



ASIC
CONGRESS 2026

ASIC COFFEE CORNER

ThS.BS. Trần Minh Trung

Tổng Thư ký Hội Tim mạch và Tim mạch Can Thiệp

An Giang

Khoa Nội Tim Mạch – BVĐK Kiên Giang



Case 1

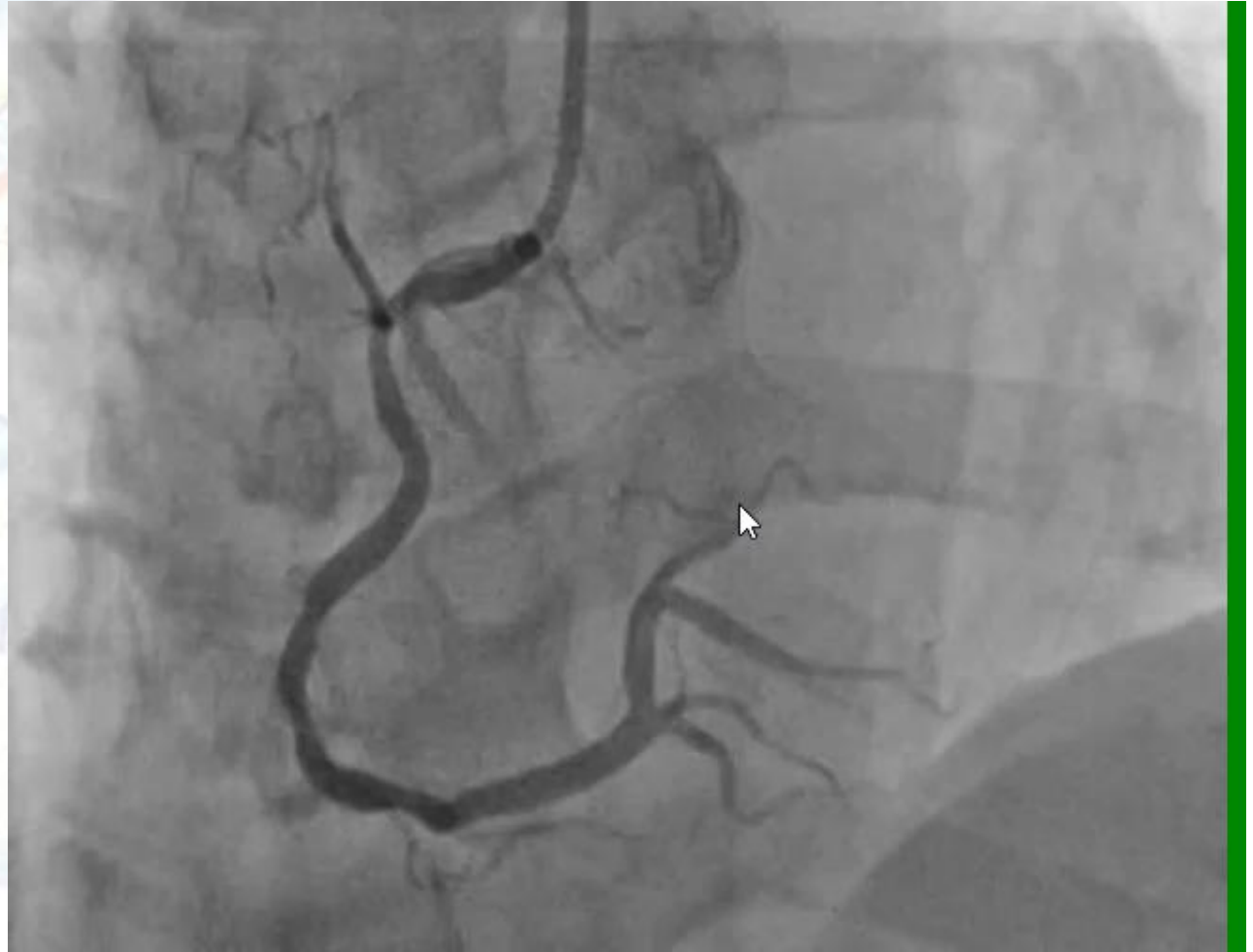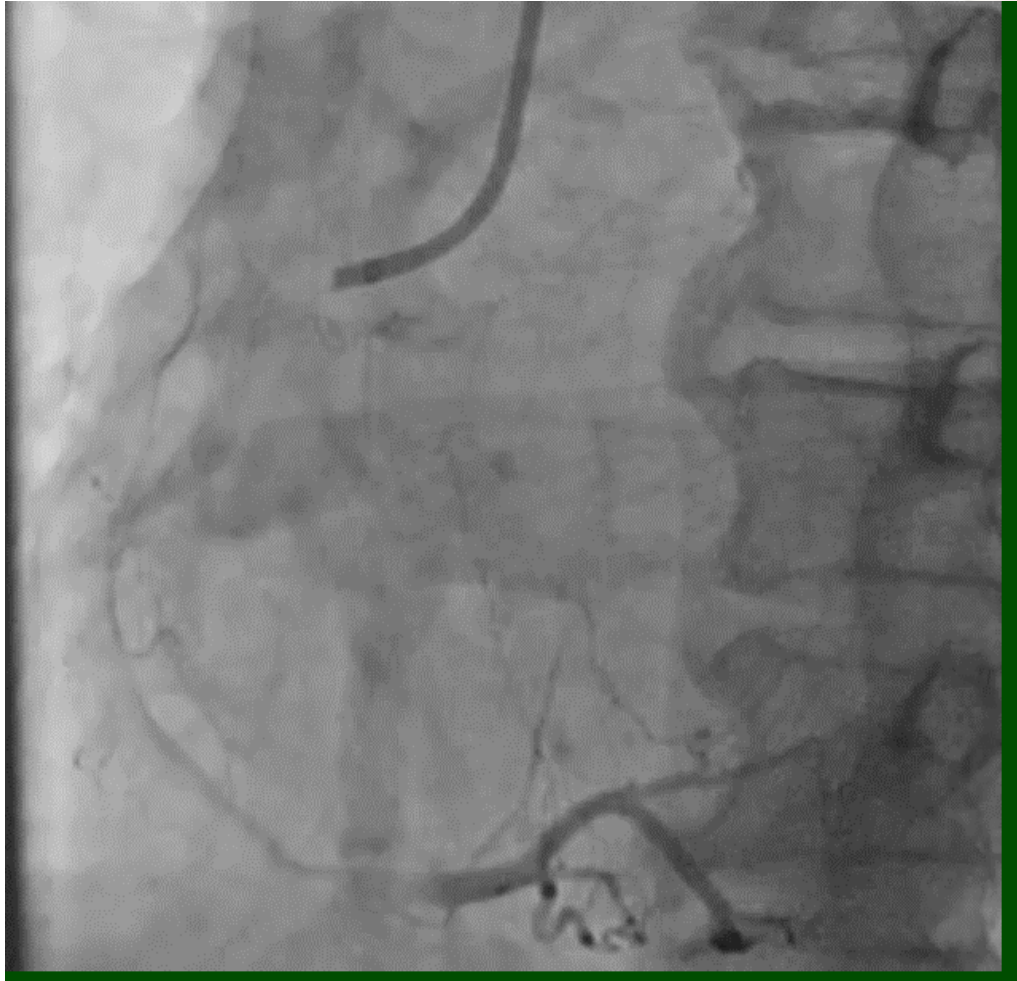LET N

Lâm sàng

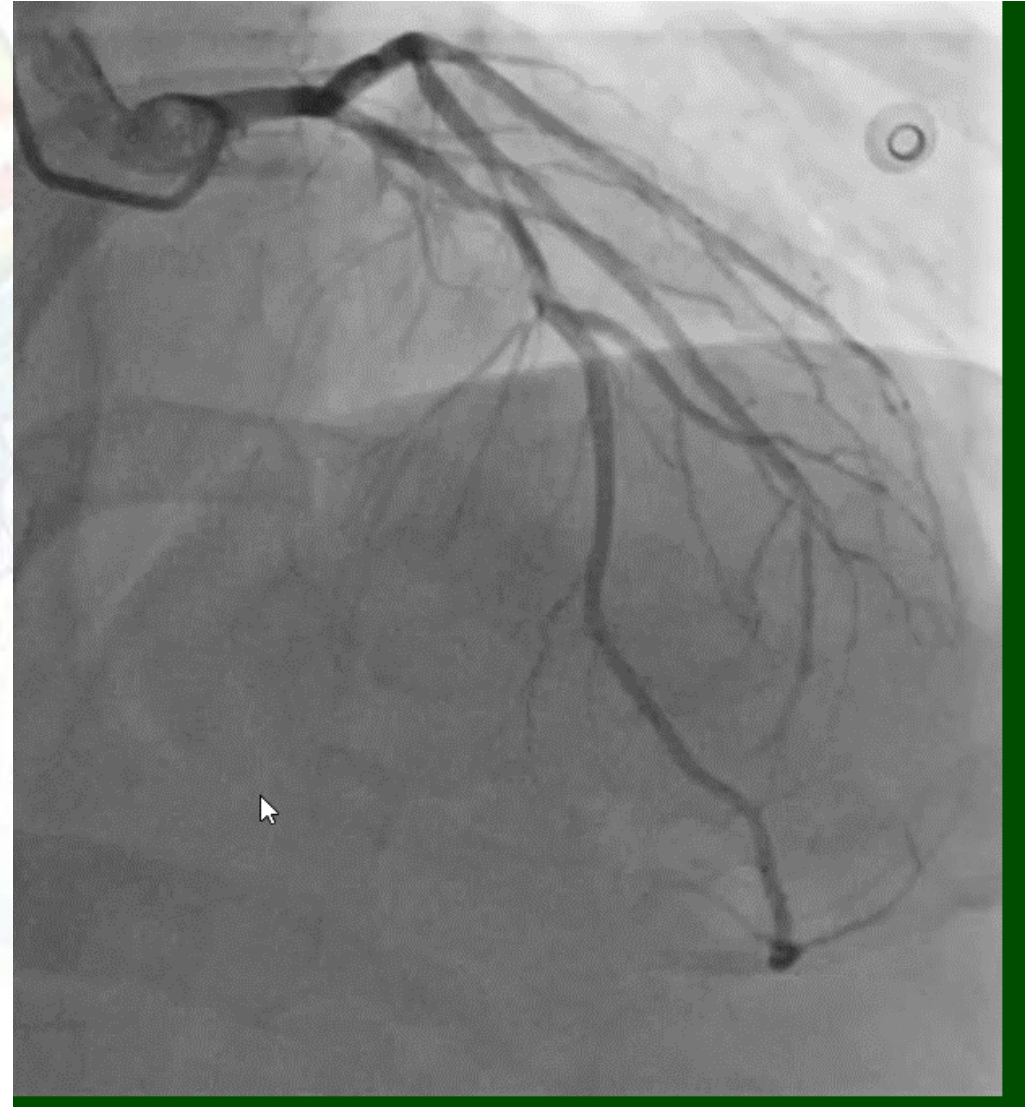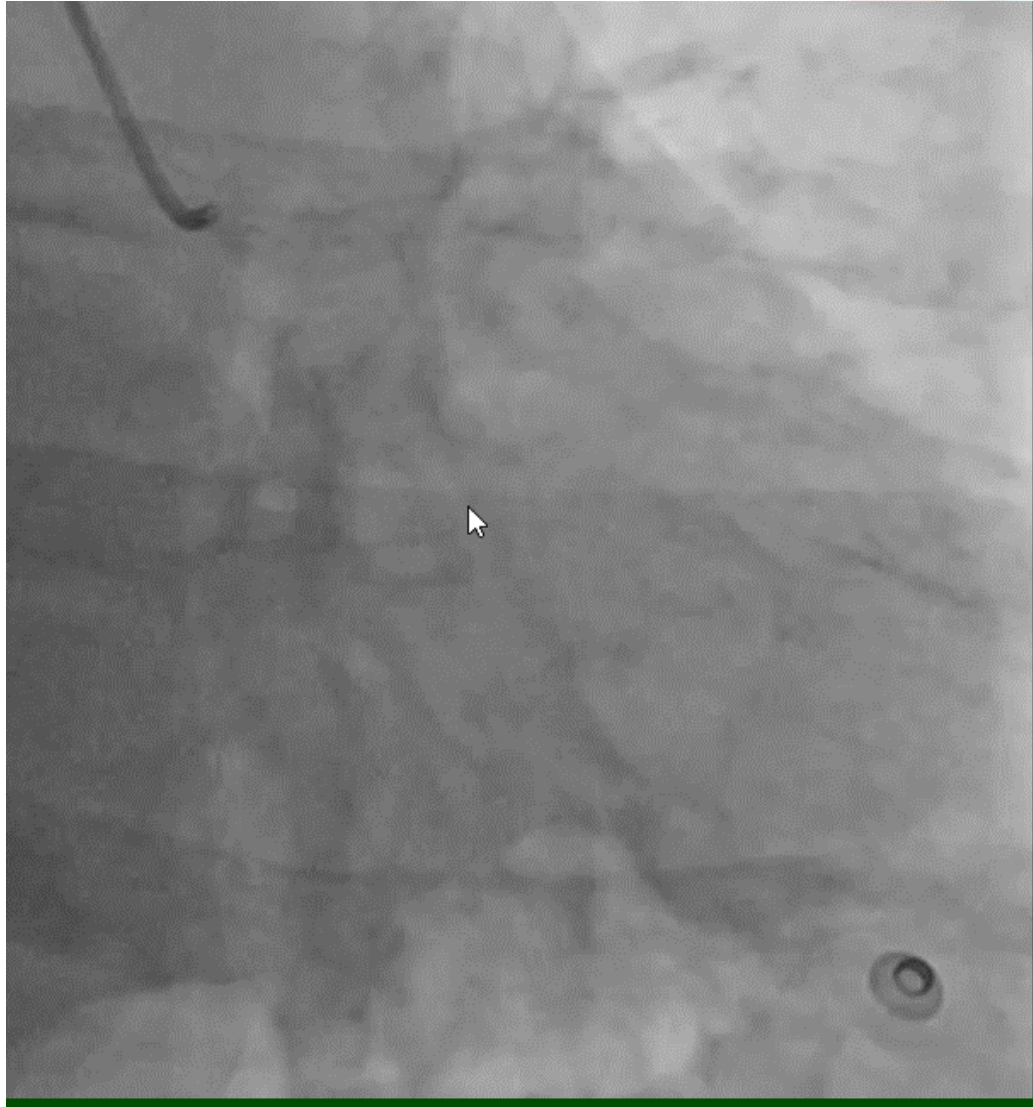An anatomical illustration of a human heart, showing the four chambers (right and left atria and ventricles) and the major blood vessels (aorta, pulmonary artery, and pulmonary veins). The heart is rendered in a semi-transparent, light blue and yellow color scheme, positioned in the background of the slide.

- Bệnh nhân: nam, 57 tuổi
- Nhập viện vì đau thắt ngực
- Chẩn đoán: **NSTEMI**
- Tiền căn: Hút thuốc lá, THA, lupus ban đỏ 1 năm

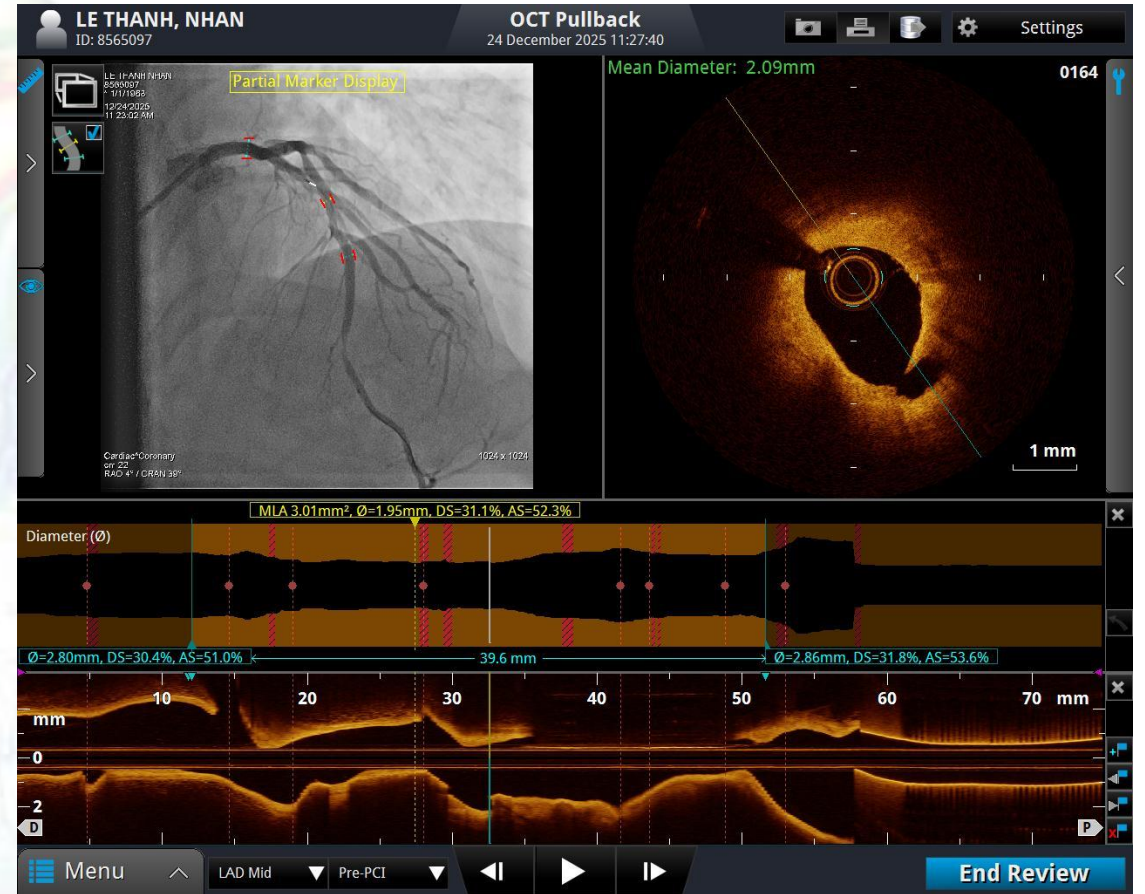
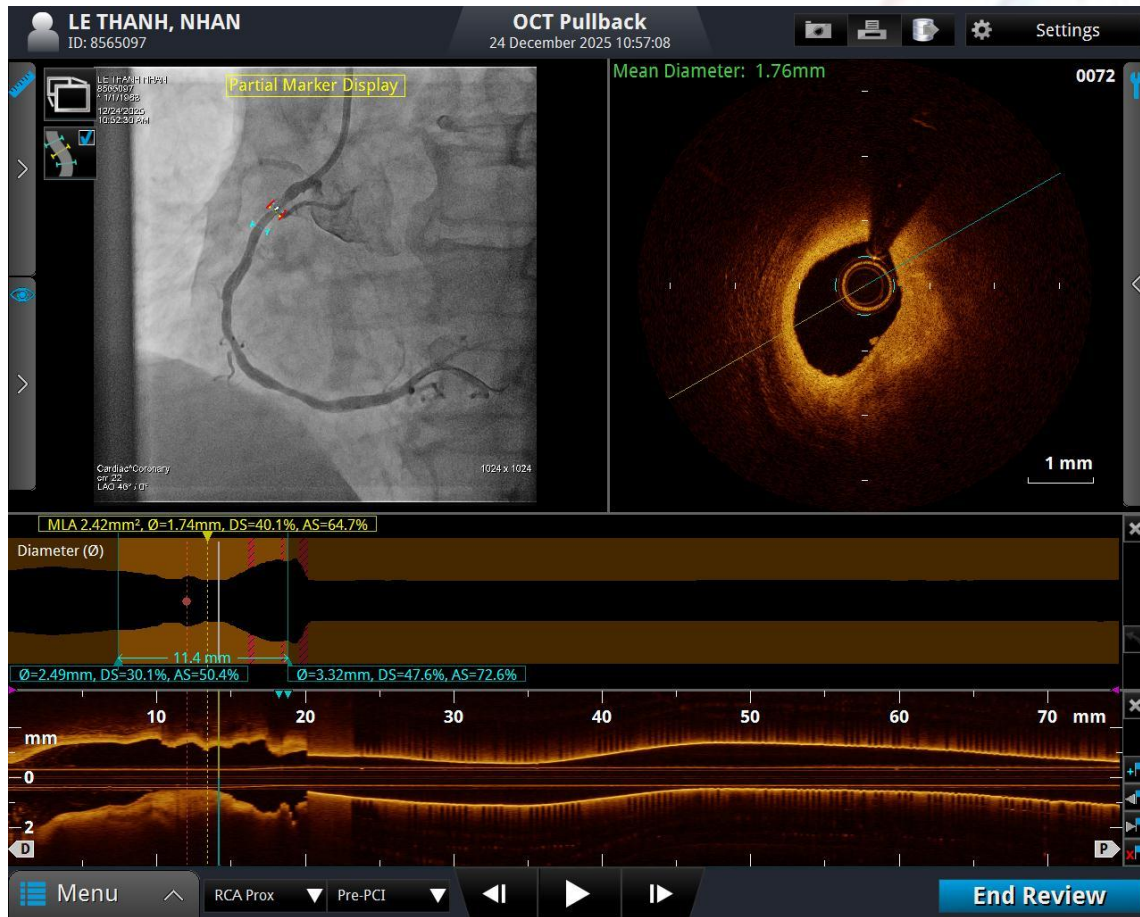
Angiogram



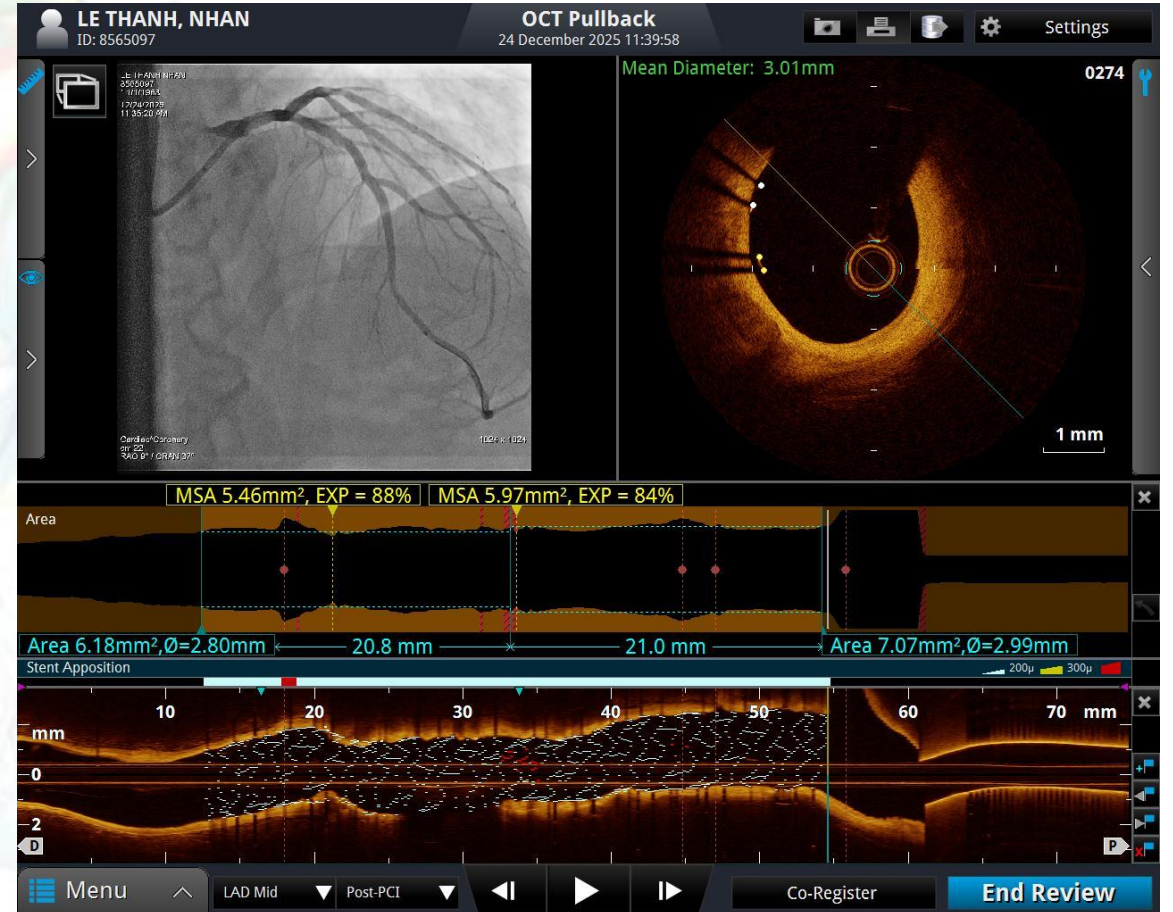
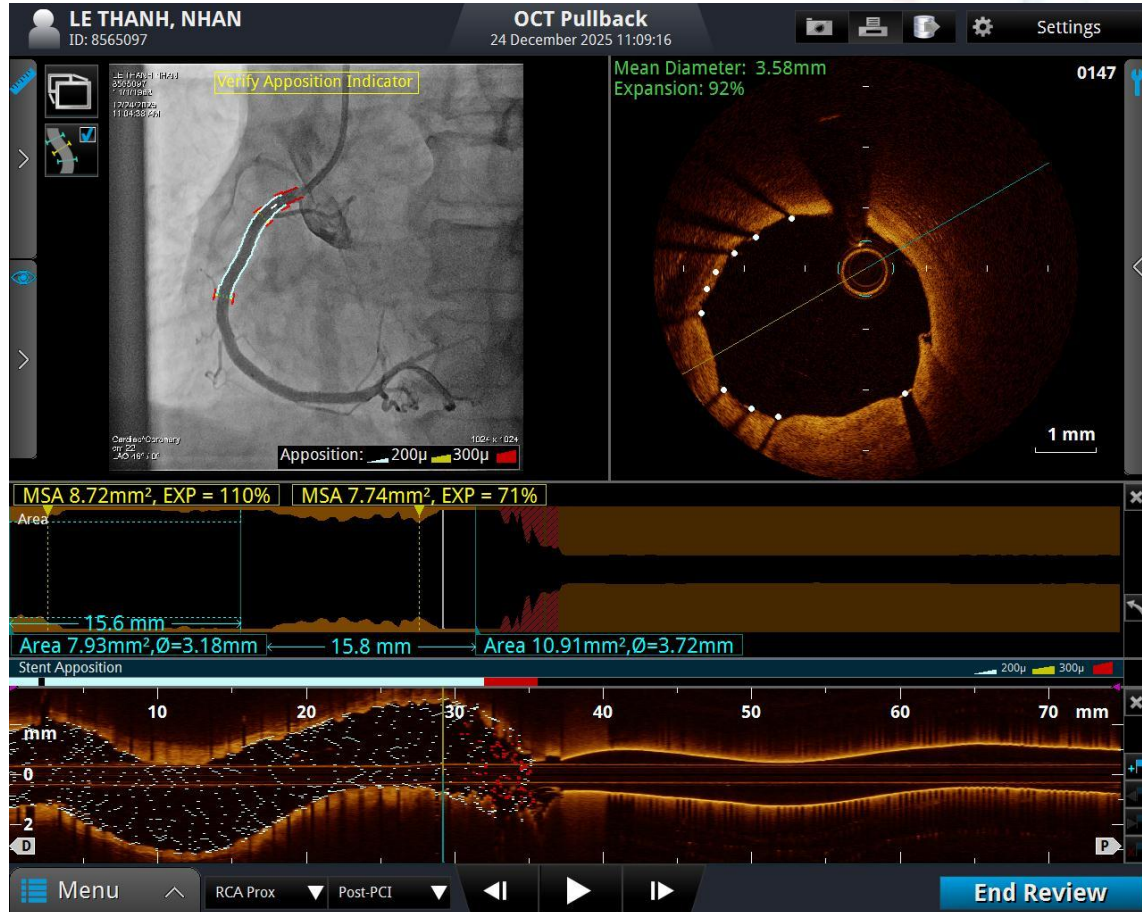
Angiogram



MLD



MAX





Case 2

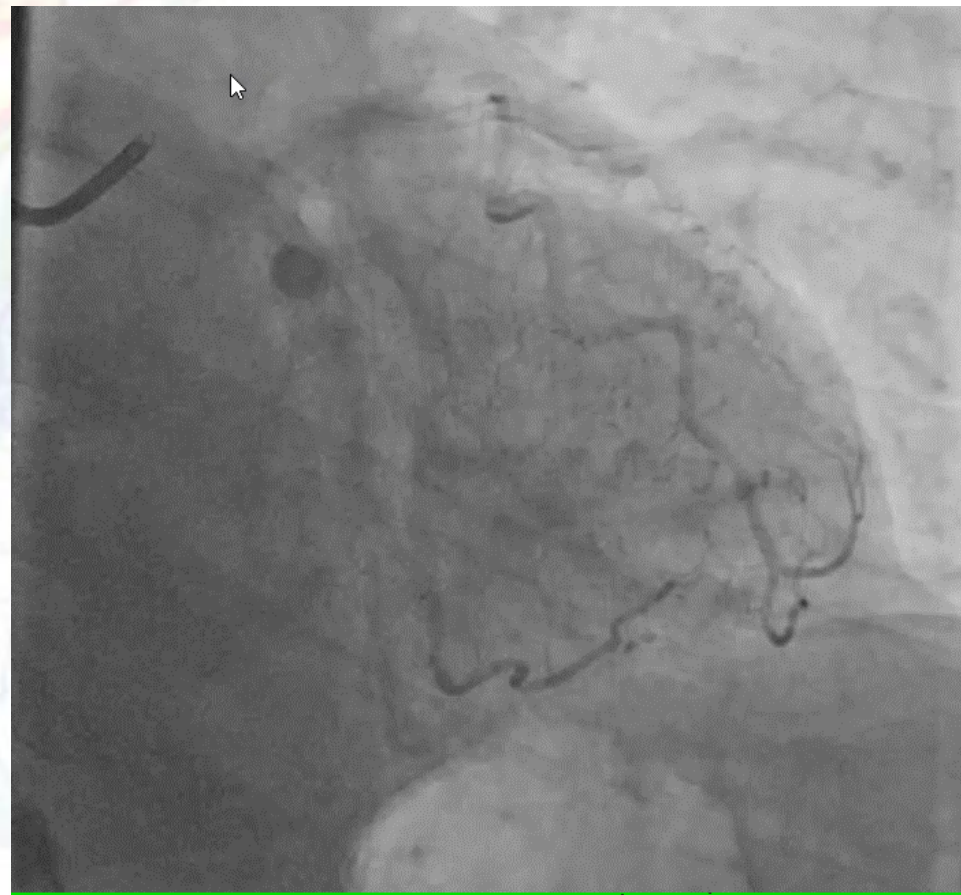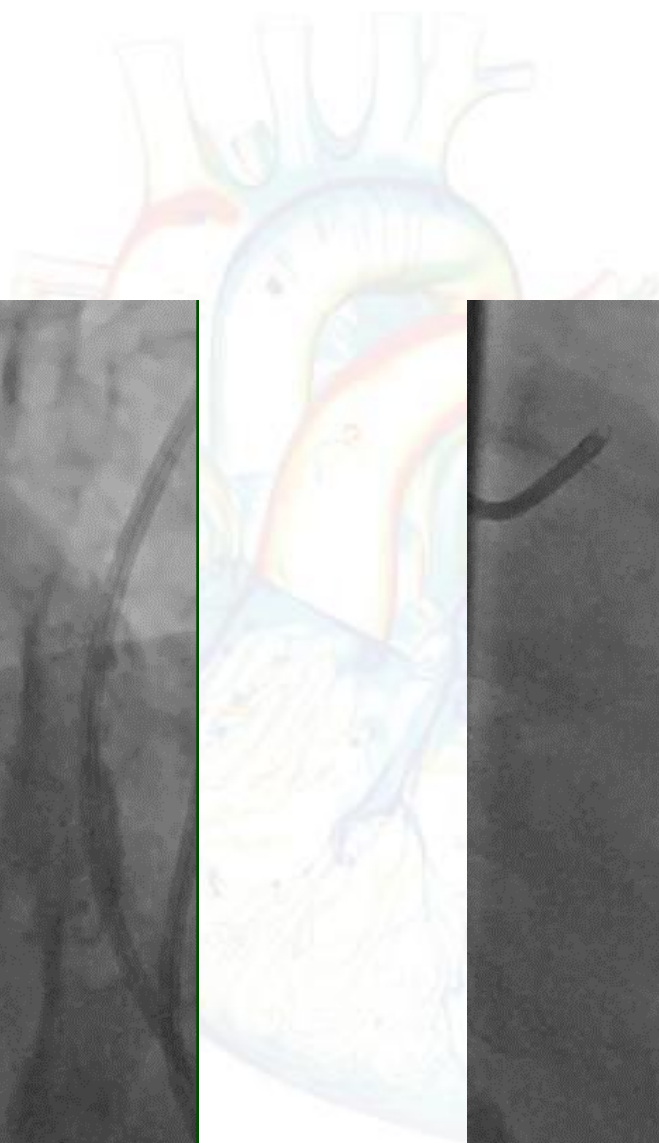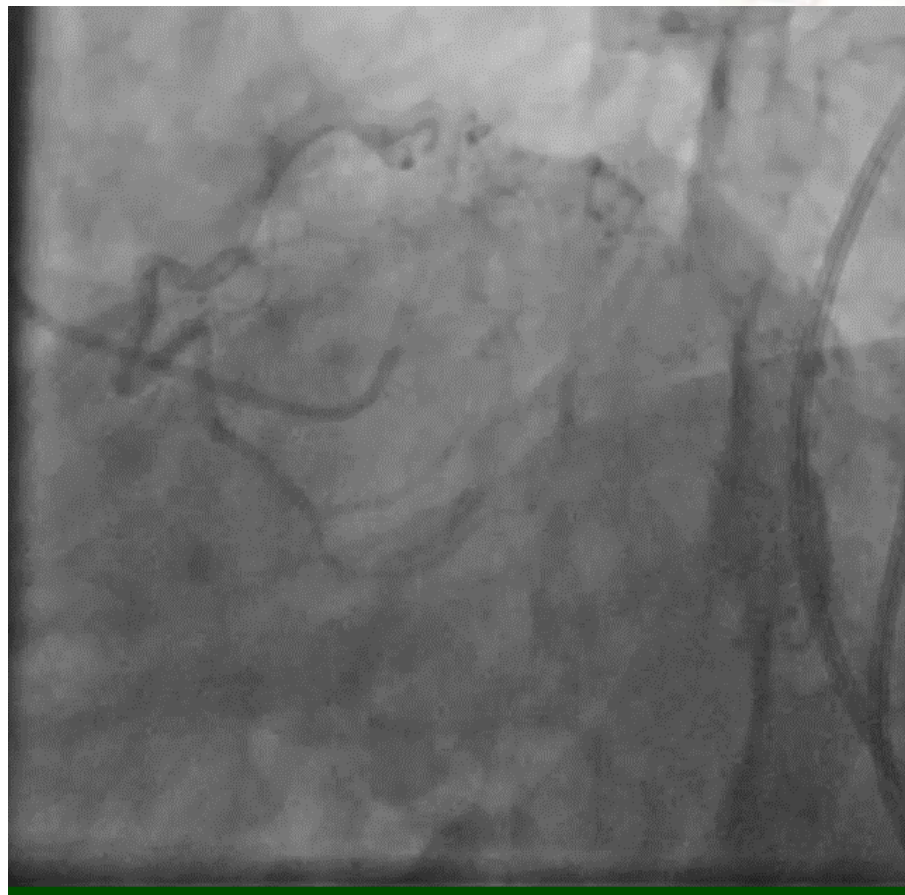
HO V T

Lâm sàng

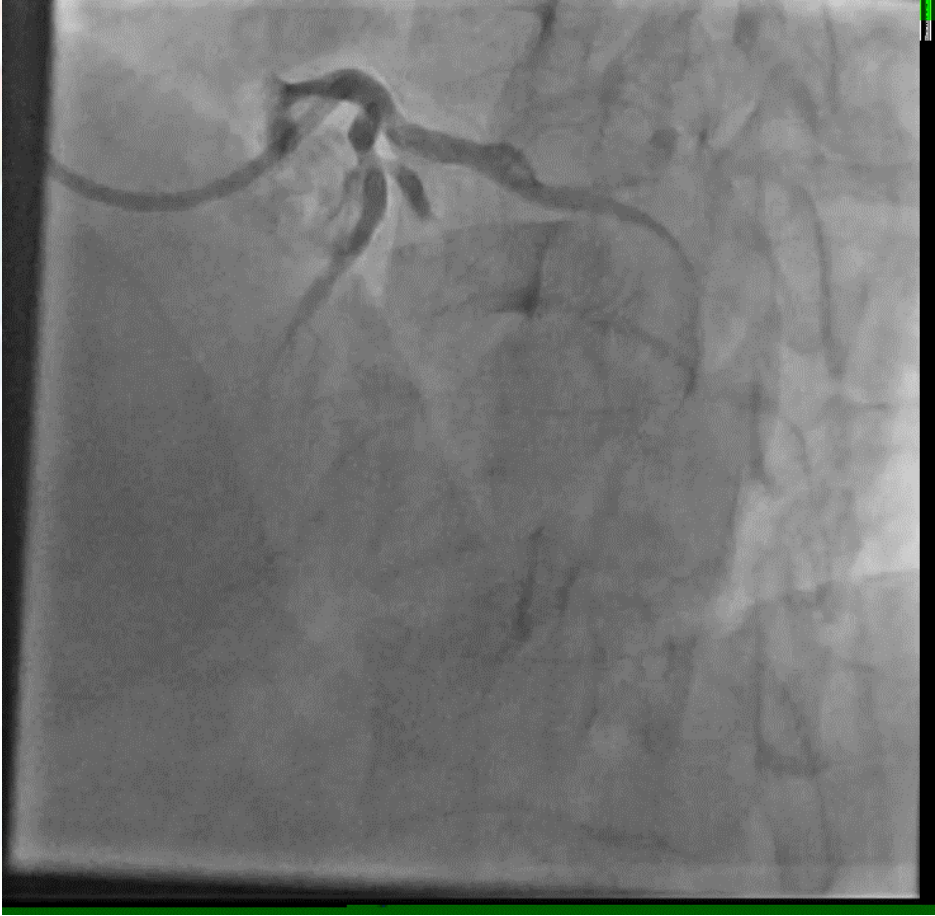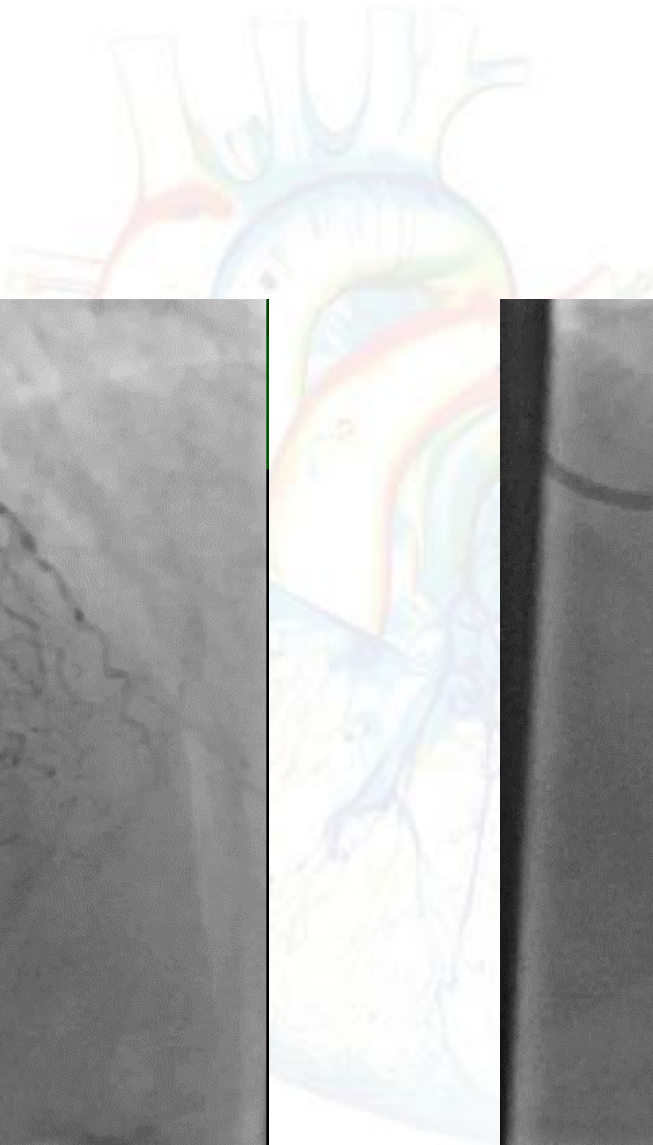
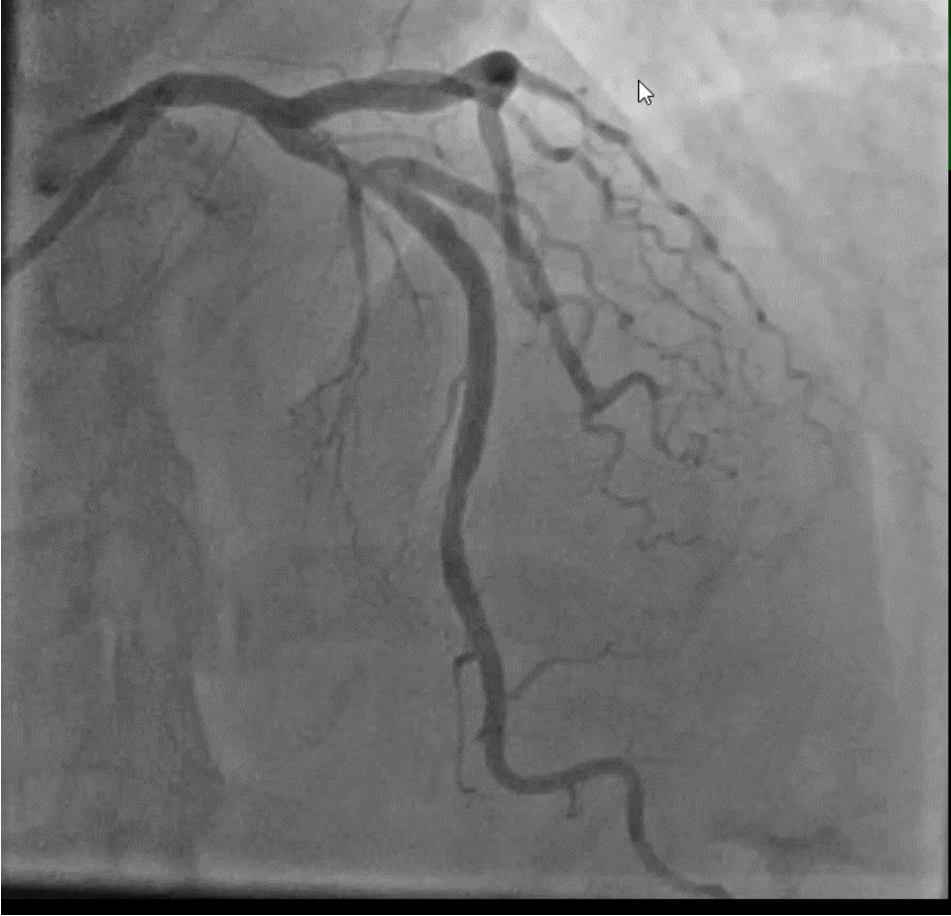An anatomical illustration of a human heart, showing the four chambers (right and left atria and ventricles) and the major blood vessels (superior and inferior vena cava, aorta, and pulmonary artery/vein). The heart is rendered in a semi-transparent, light blue and yellow color scheme, positioned in the background of the slide.

- Bệnh nhân nam, 56 tuổi
- Vào viện đau thắt ngực
- Chẩn đoán: **STEMI**
- Tiền sử: Hút thuốc lá, Cường giáp đã điều trị

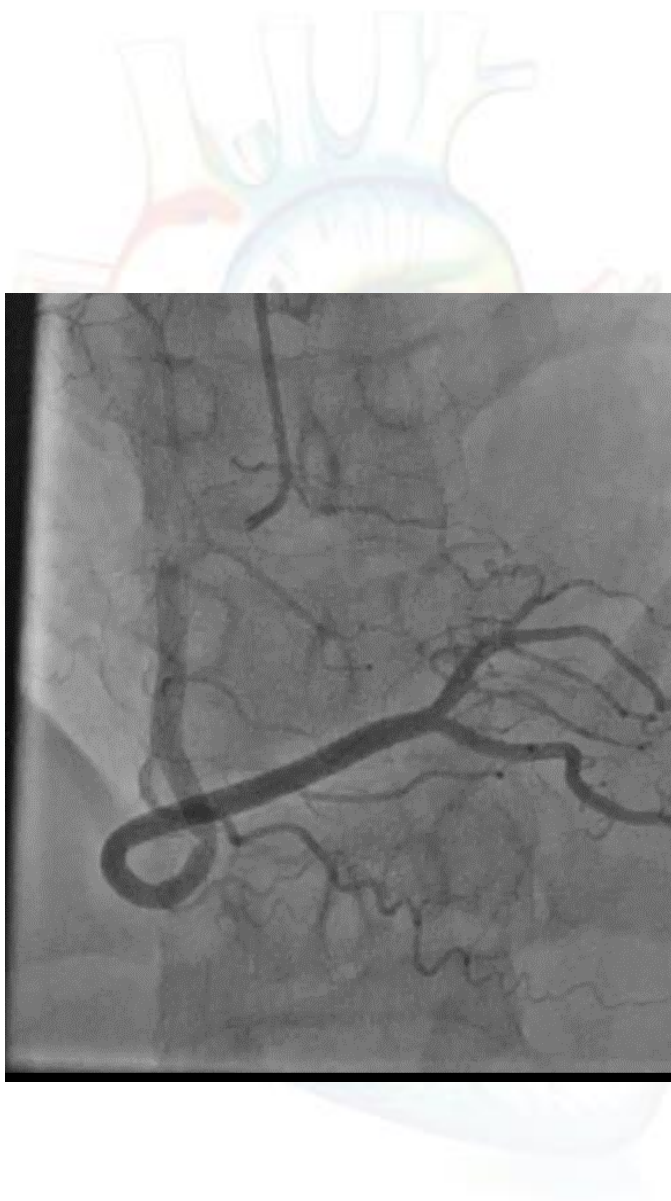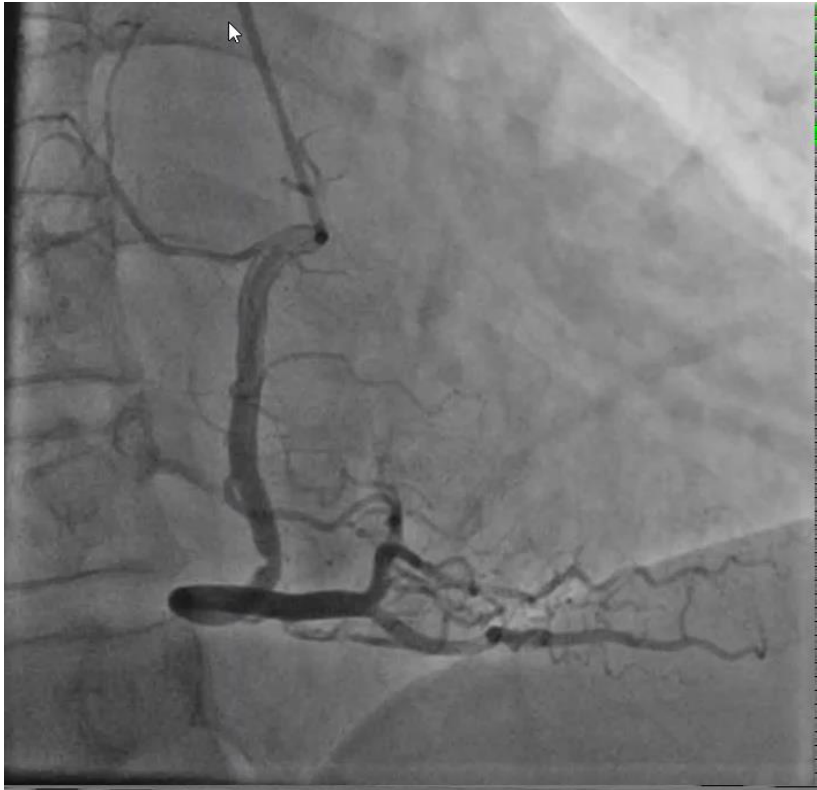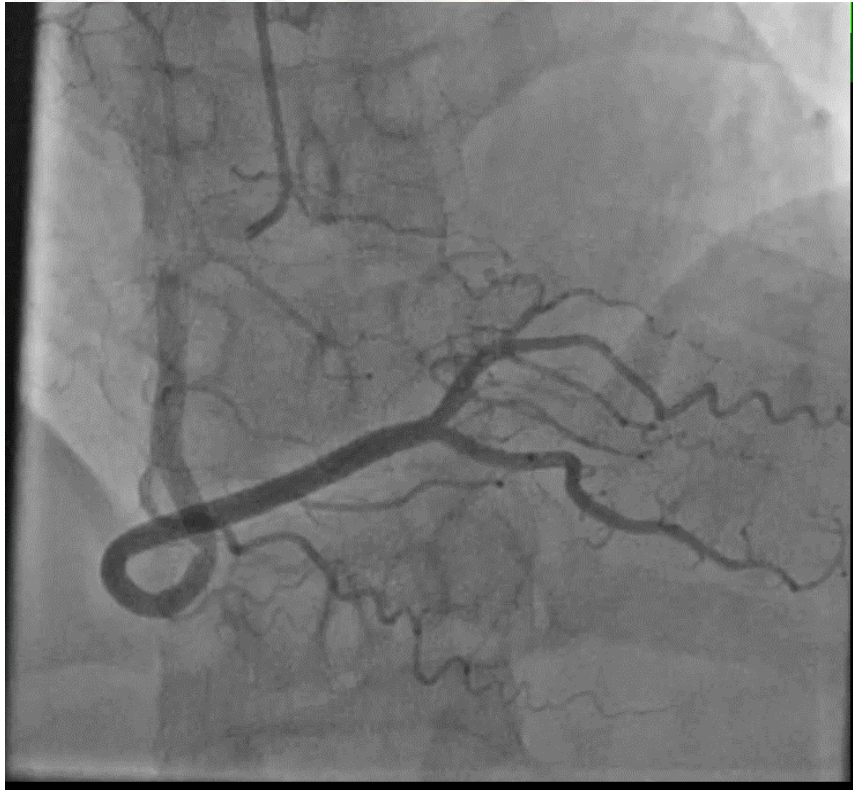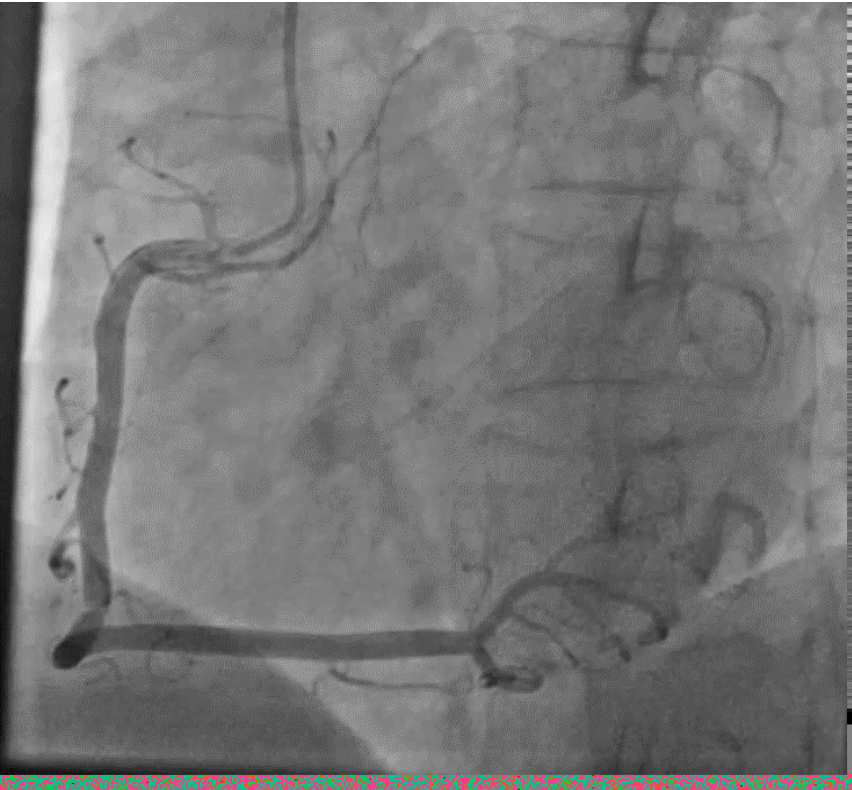Angiogram



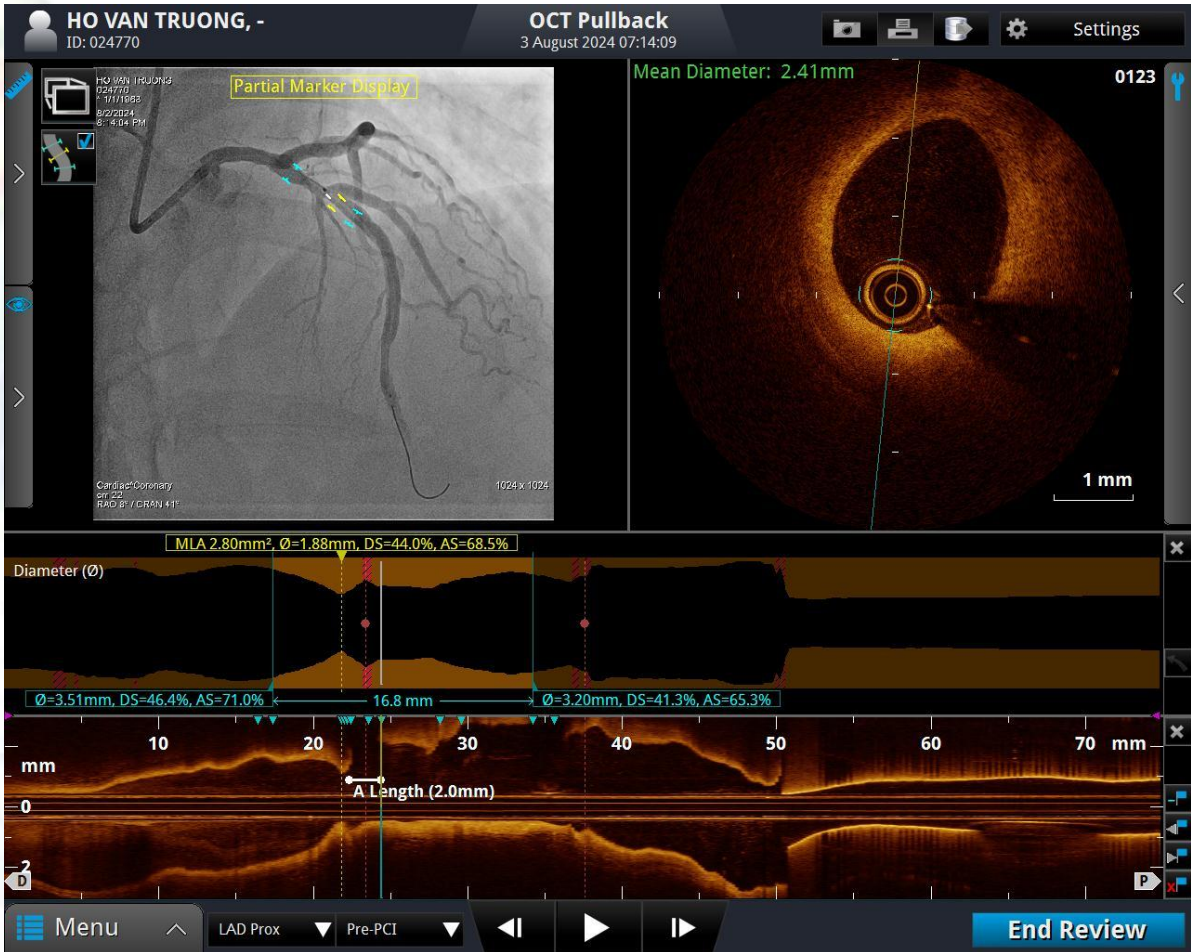
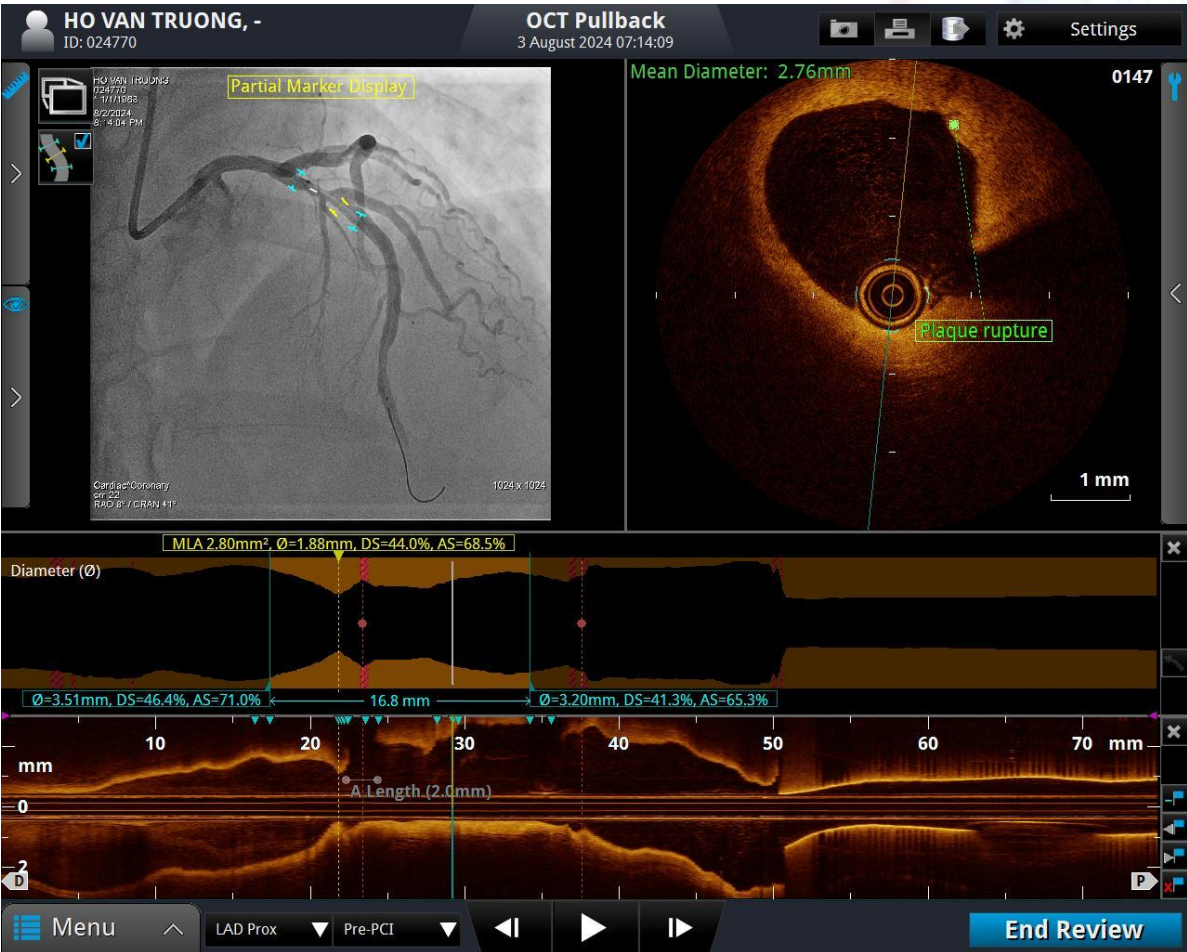
Angiogram



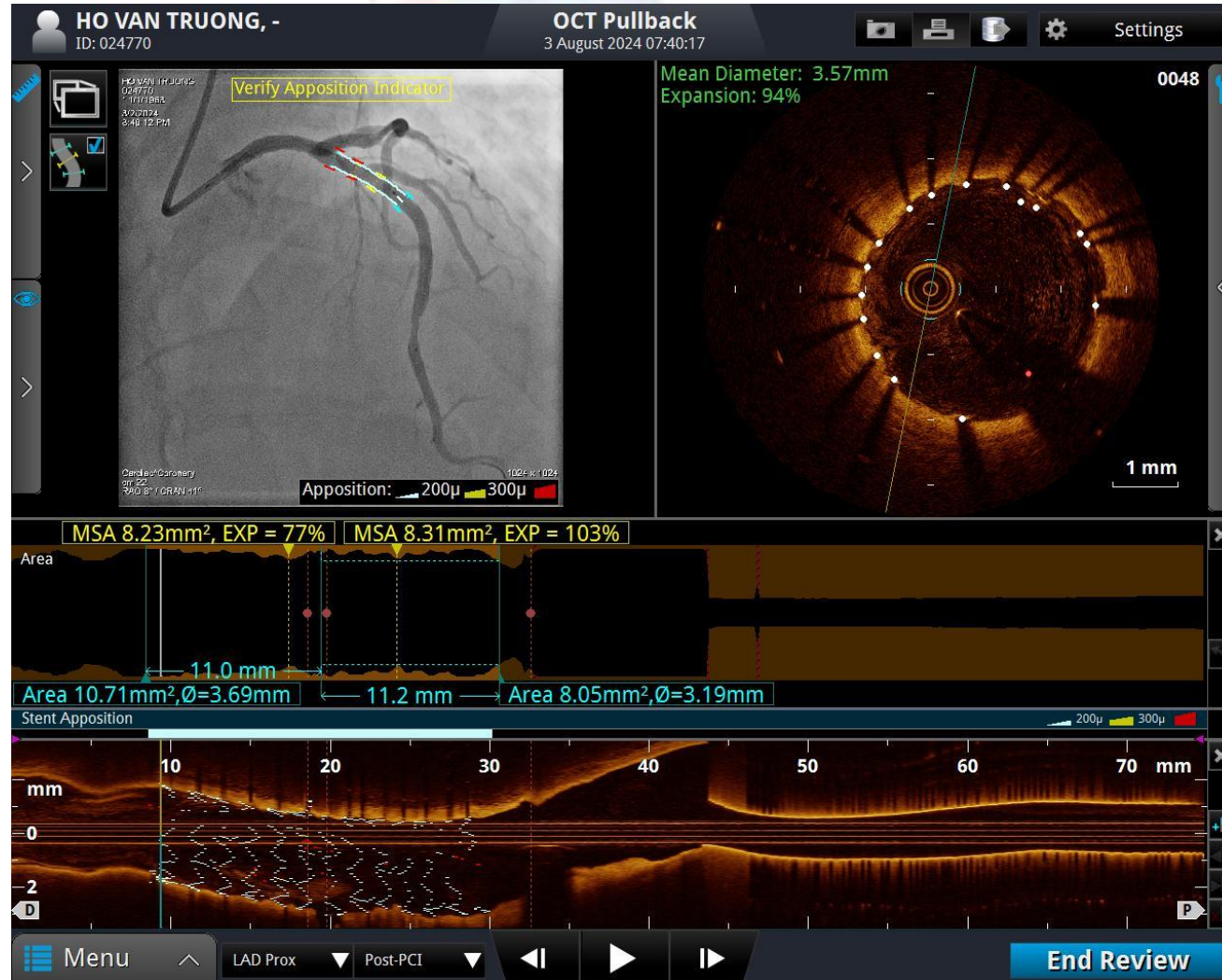
Angiogram



MLD



MAX



Thank you for your attention !

