

Case 1

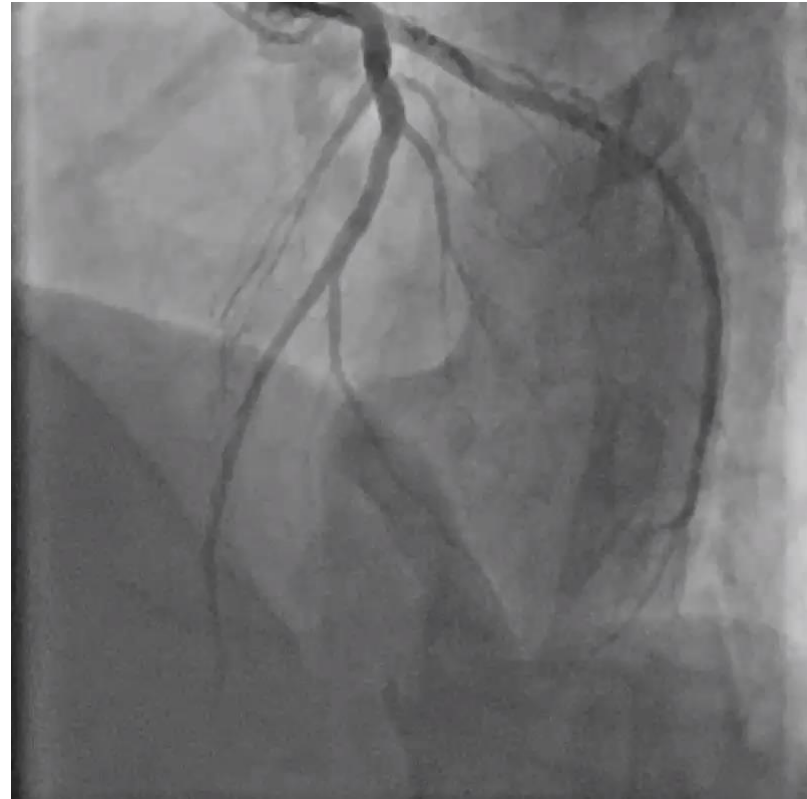
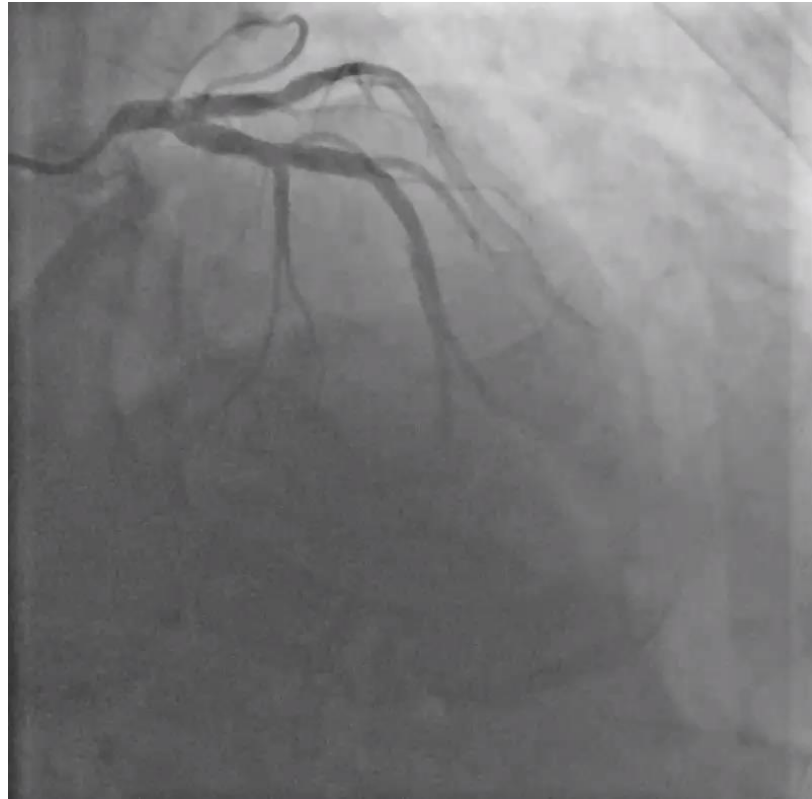
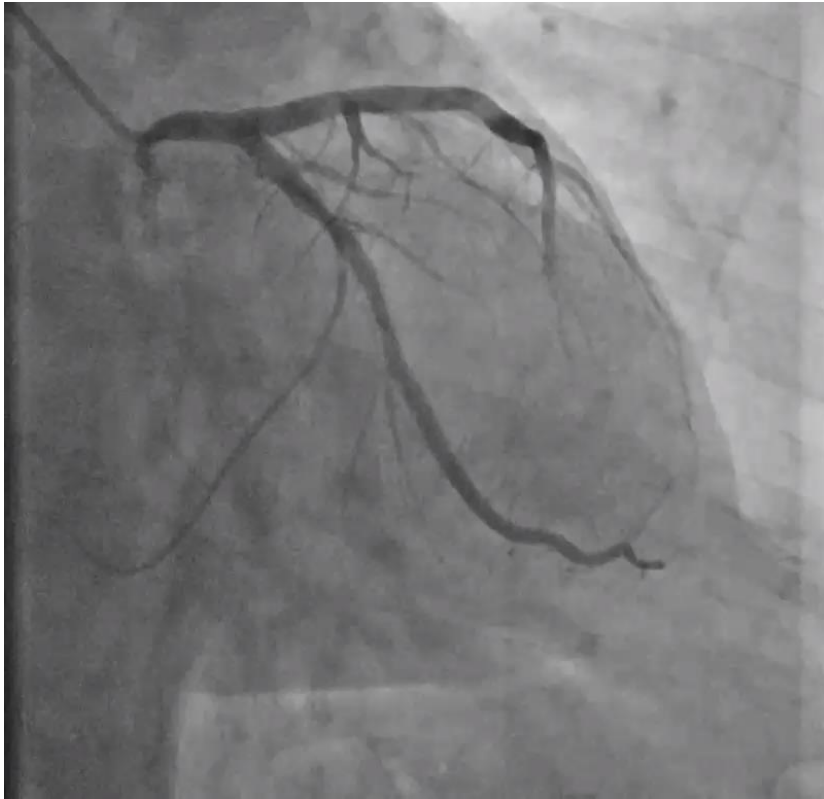
TRAN MINH H

ThS. BS. Trần Minh Trung

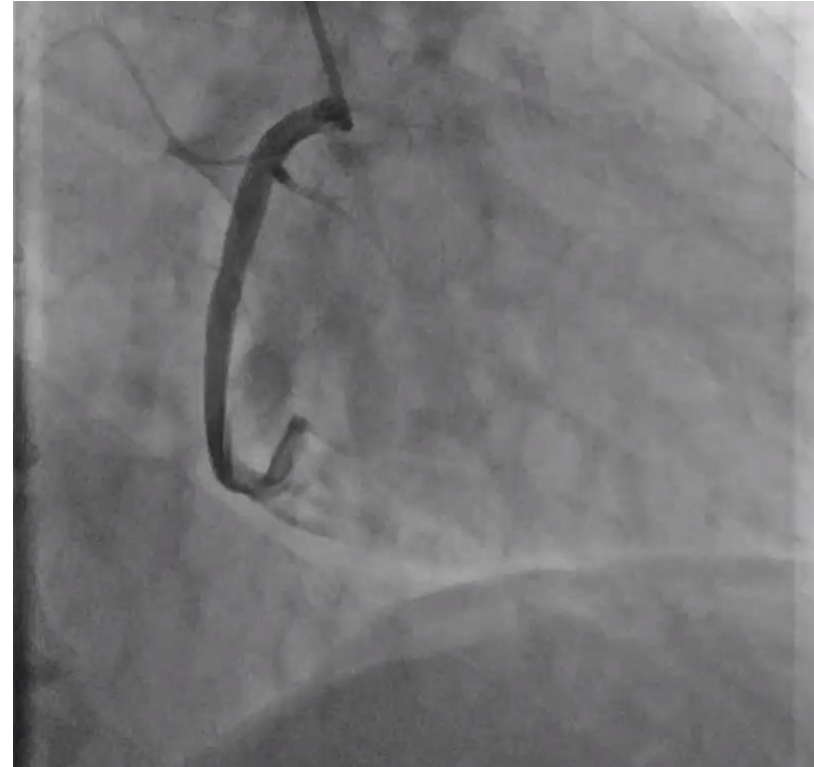
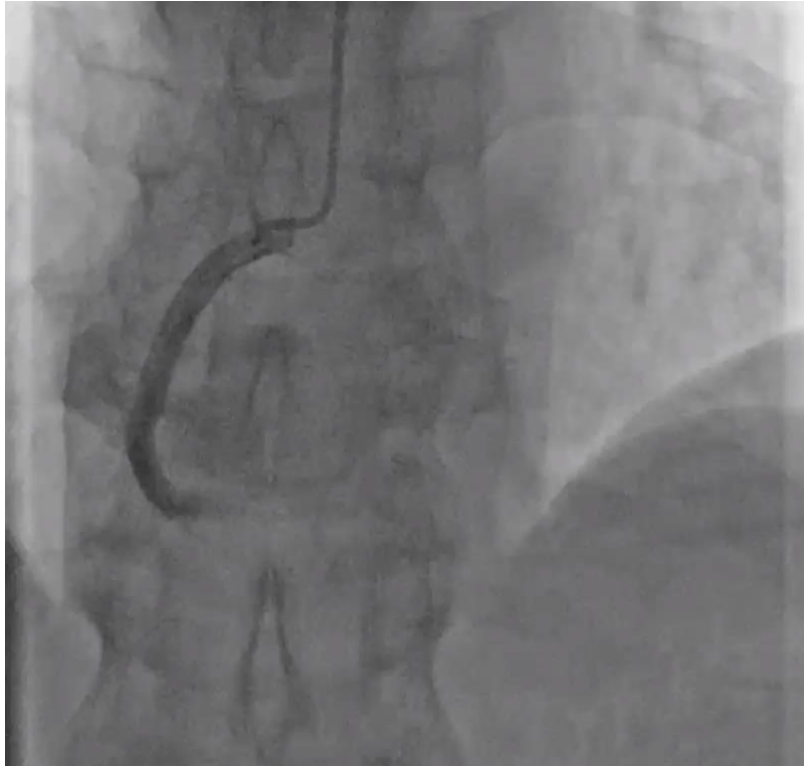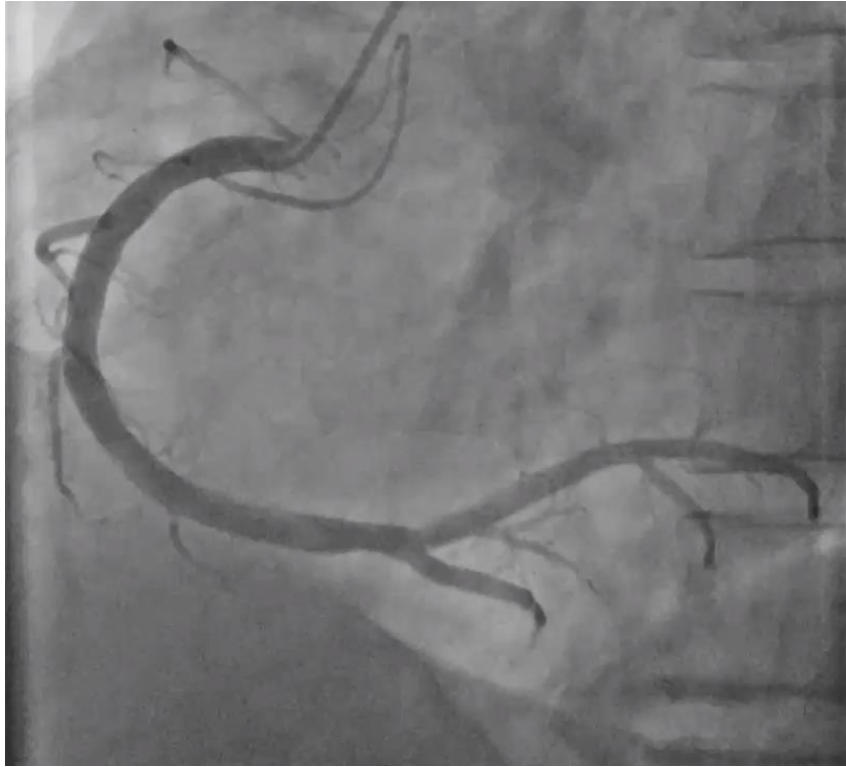Lâm sàng

- Bệnh nhân: nam, 63 tuổi
- Nhập viện vì đau thắt ngực
- Chẩn đoán: **NSTEMI**
- Tiền căn: Hút thuốc lá, THA, BMV đã đặt stent LCx (2023)

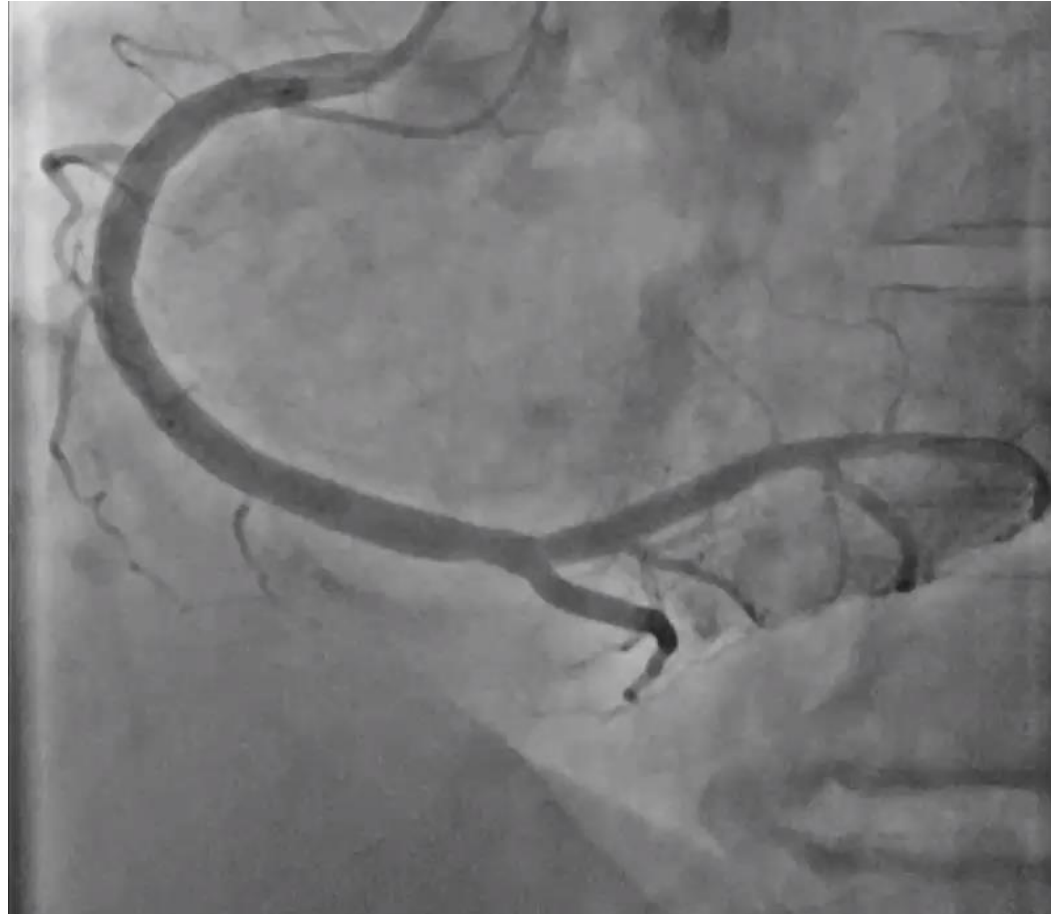Angiogram



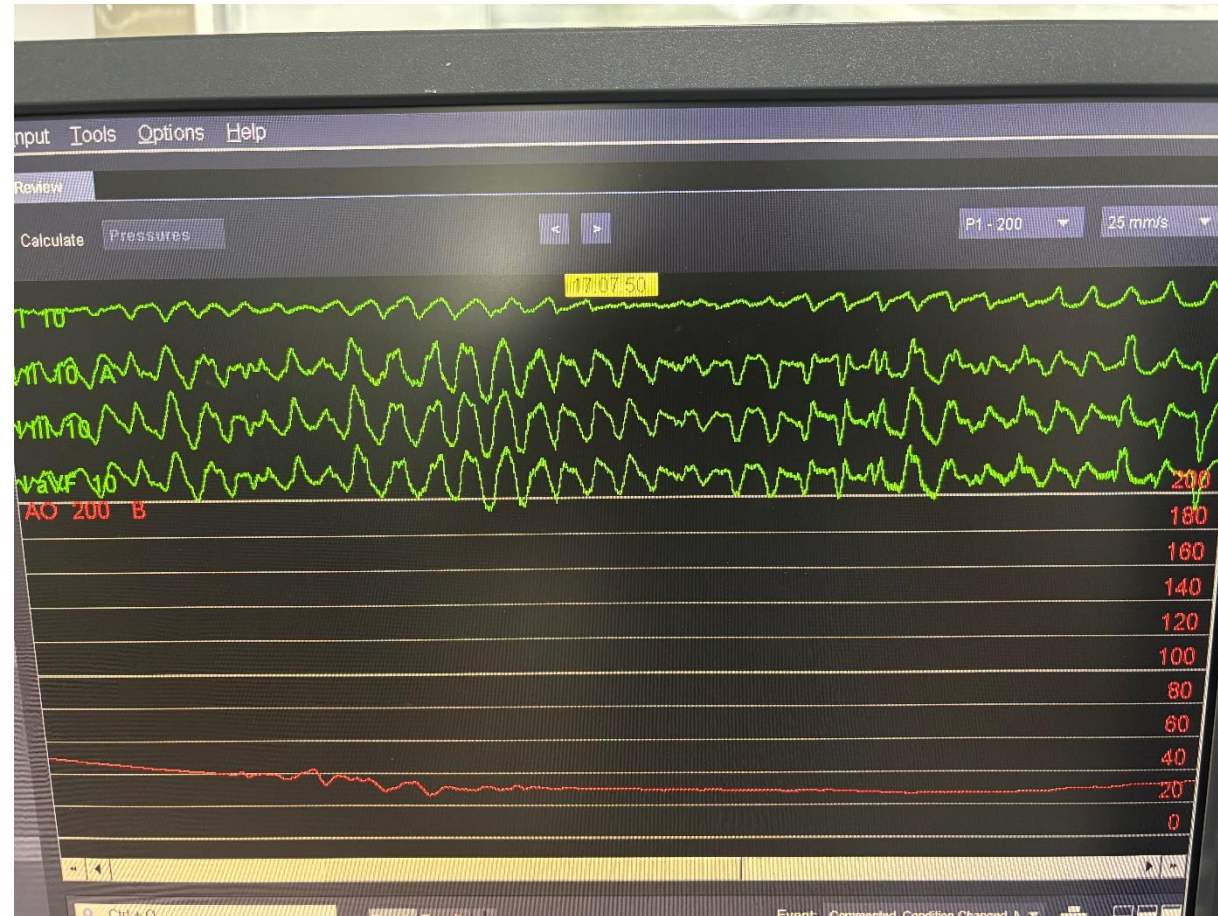Angiogram



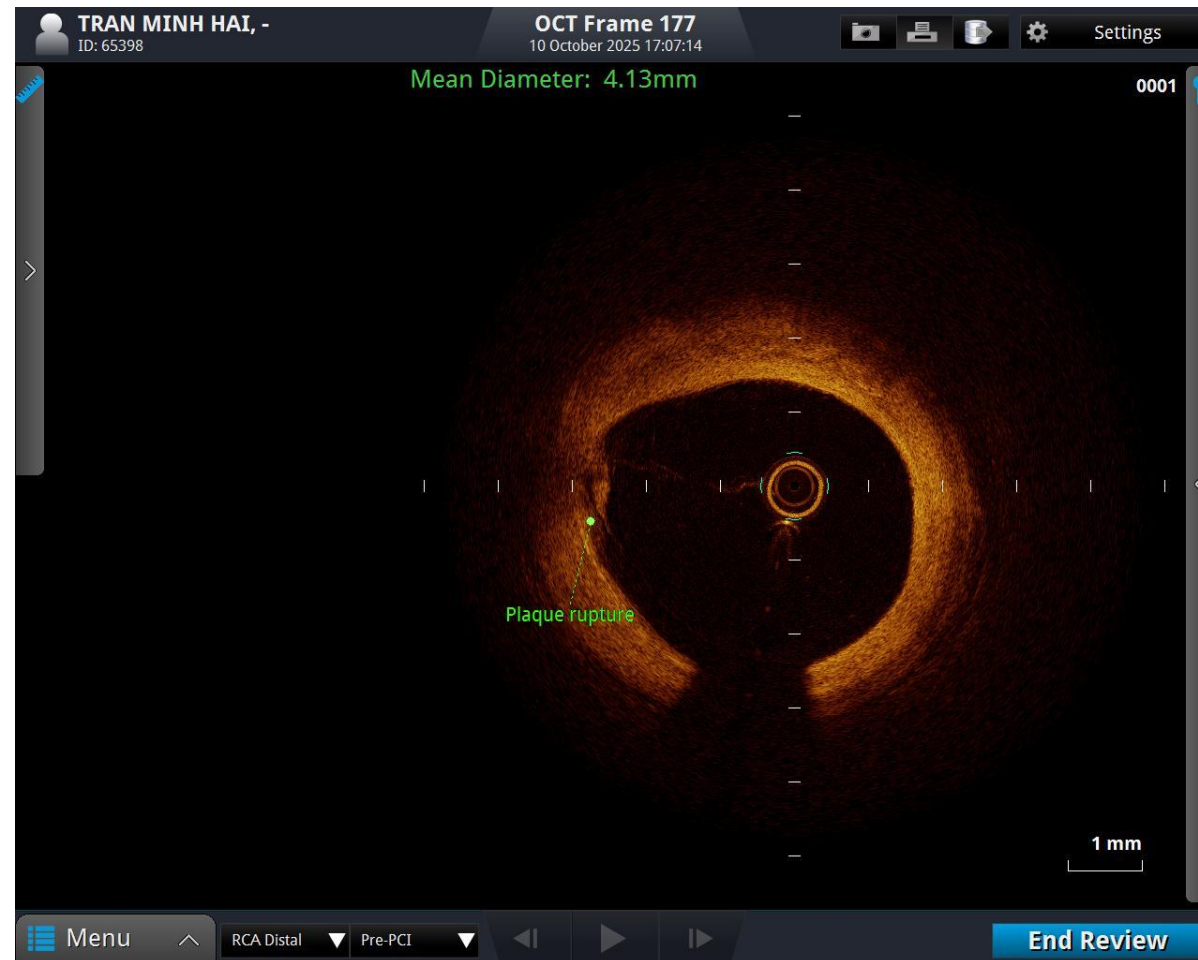
Pre PCI OCT RCAIII



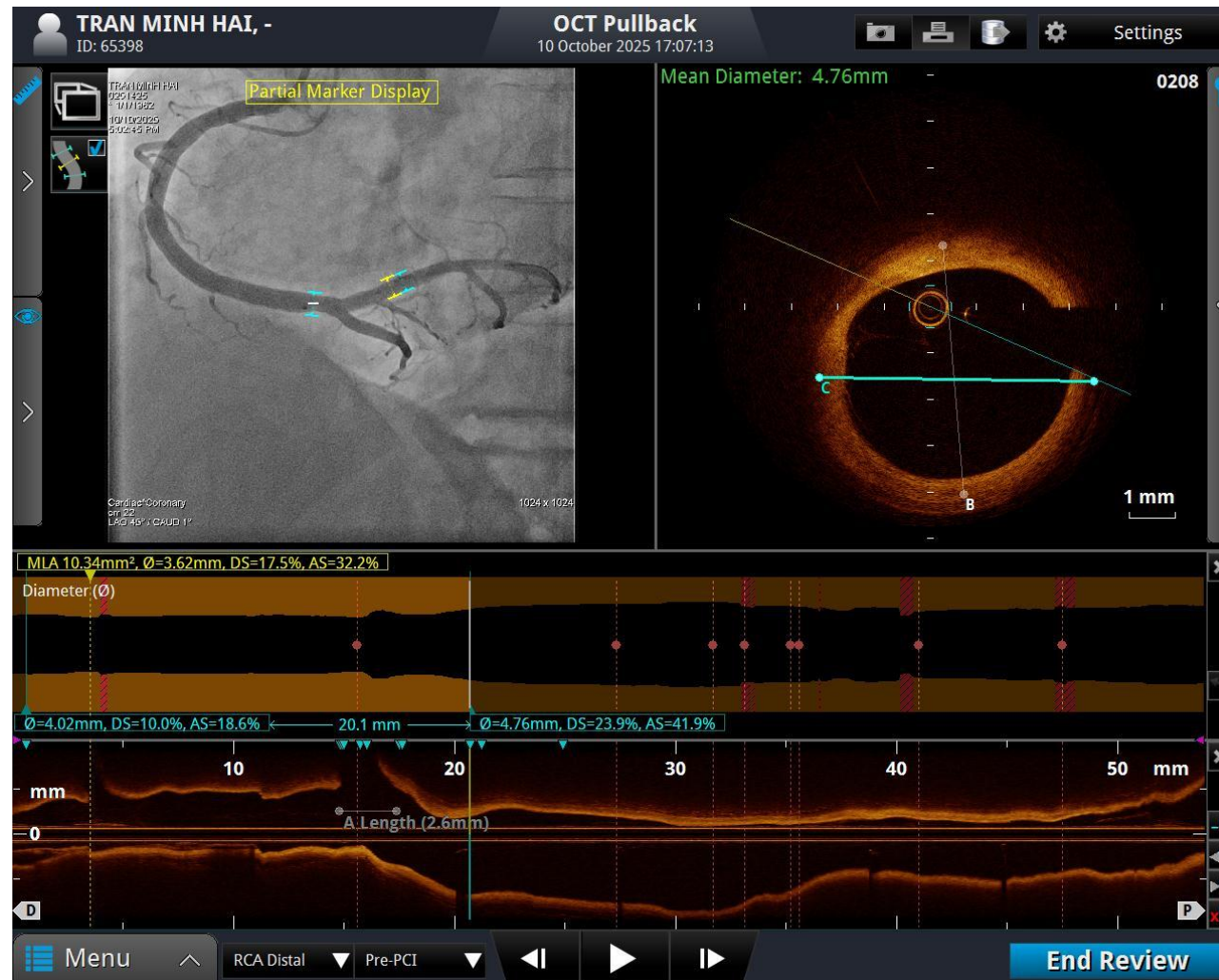
After OCT Pullback



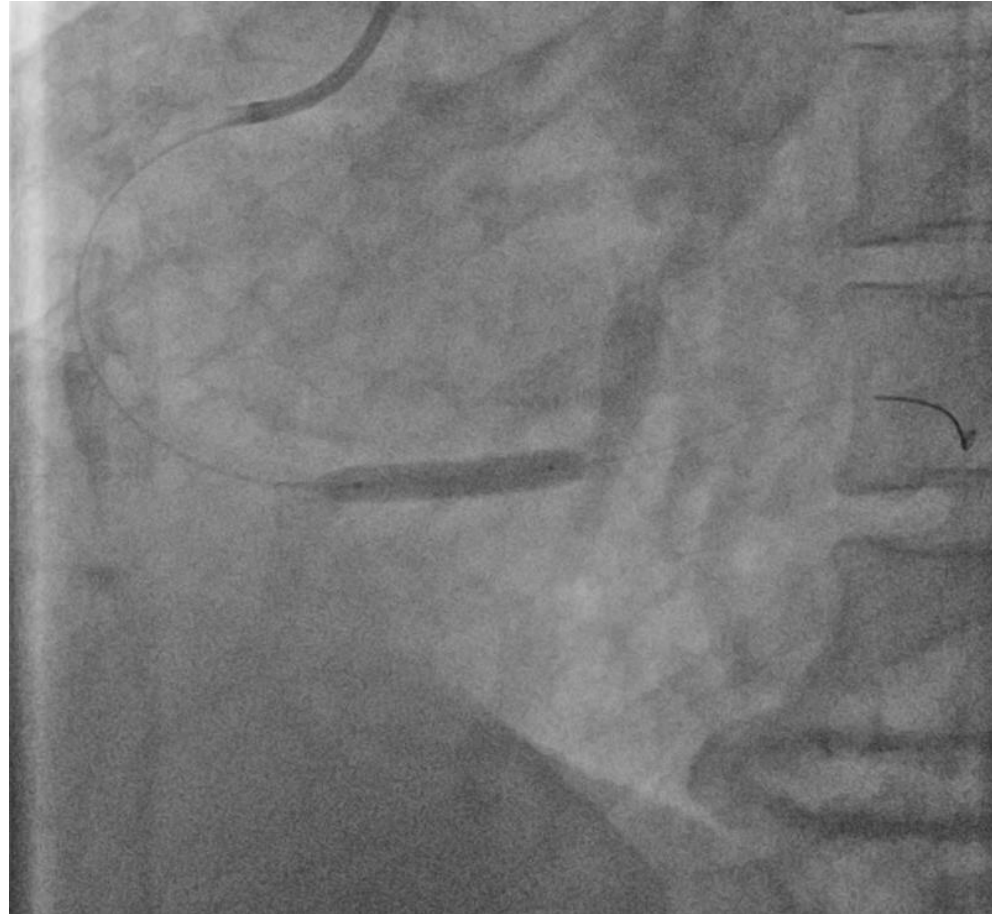OCT imagings



MLD



DES 4.0*19mm, Post dilatation 4.5*10mm
NC Balloon



MAX

