



**ASIC**  
CONGRESS 2026

# ASIC COFFEE CORNER

---

**ThS.BS. Trần Minh Trung**

**Tổng Thư ký Hội Tim mạch và Tim mạch Can Thiệp**

**An Giang**

**Khoa Nội Tim Mạch – BVĐK Kiên Giang**



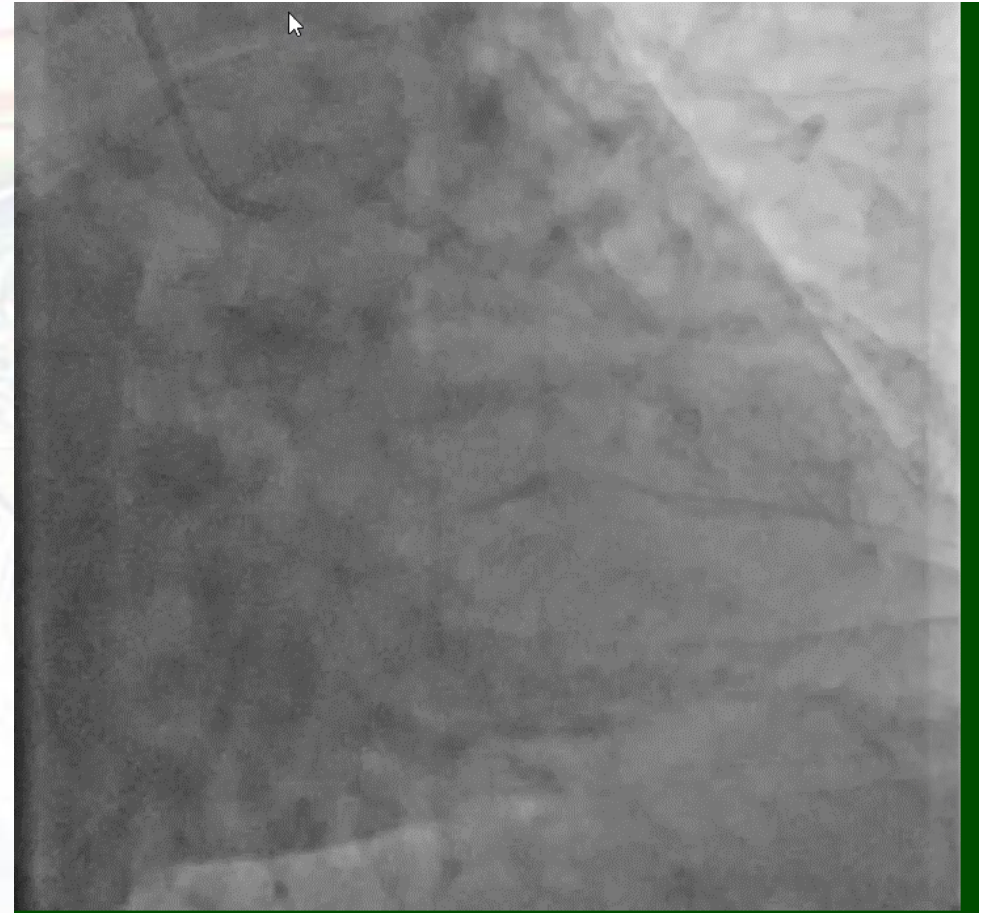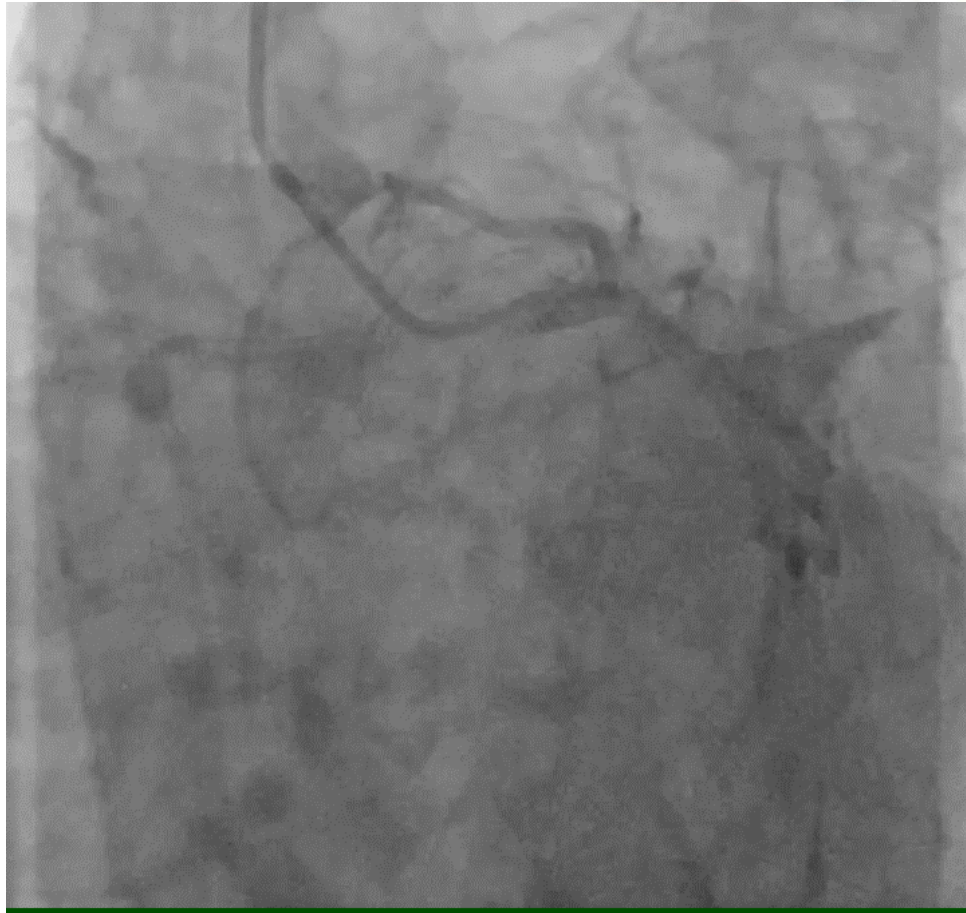# Case TRAN T T

# Lâm sàng

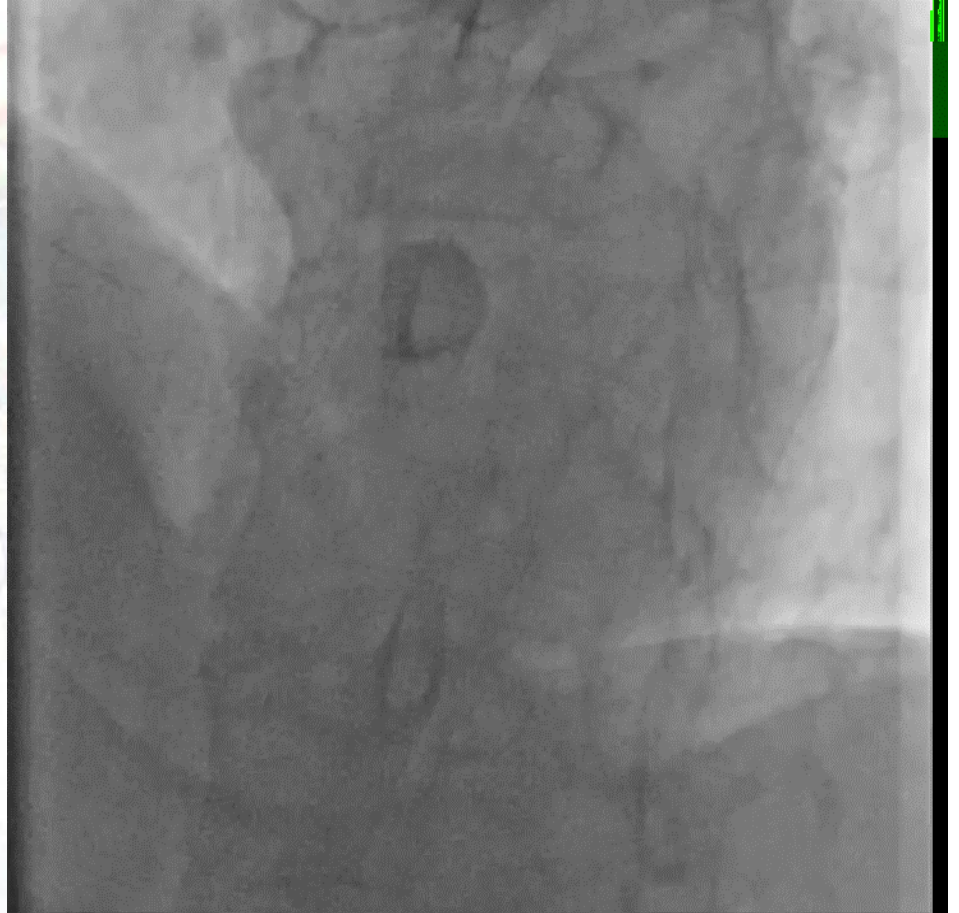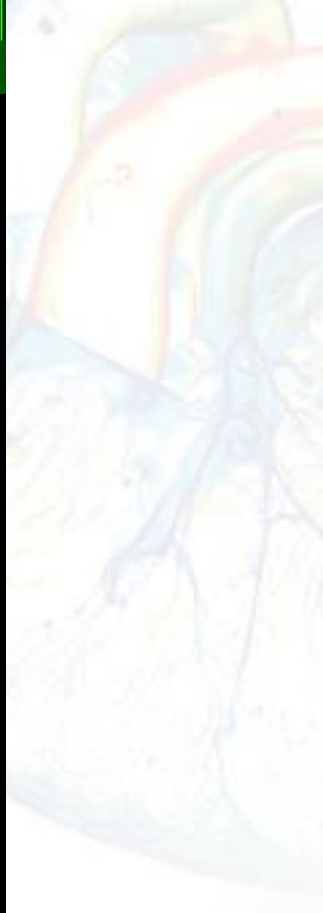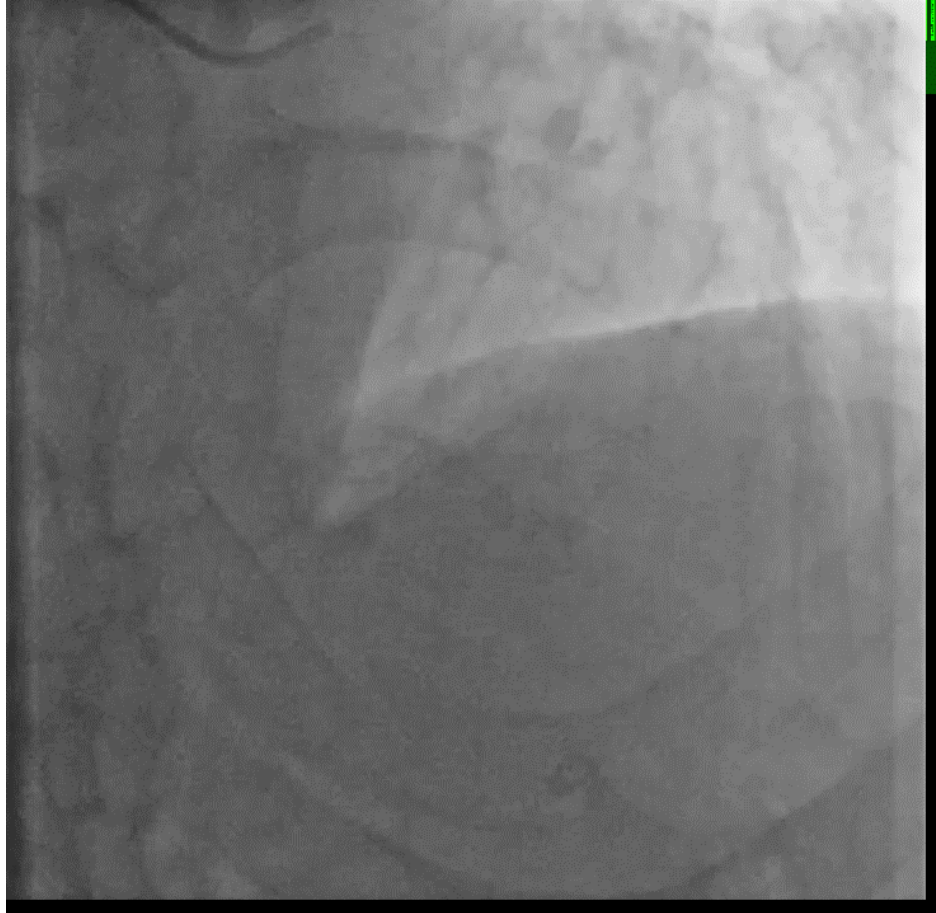An anatomical illustration of the human heart, showing the four chambers (right and left atria and ventricles) and the major blood vessels (aorta, pulmonary artery, and pulmonary veins). The heart is rendered in a semi-transparent, light blue and yellow color scheme, positioned in the background of the slide.

- Bệnh nhân nam, 82 tuổi
- Vào viện vì mệt, khó thở
- Chẩn đoán: **CCS**
- Tiền sử: THA, NSTEMI đã stent RCA, Di chứng nhồi máu não

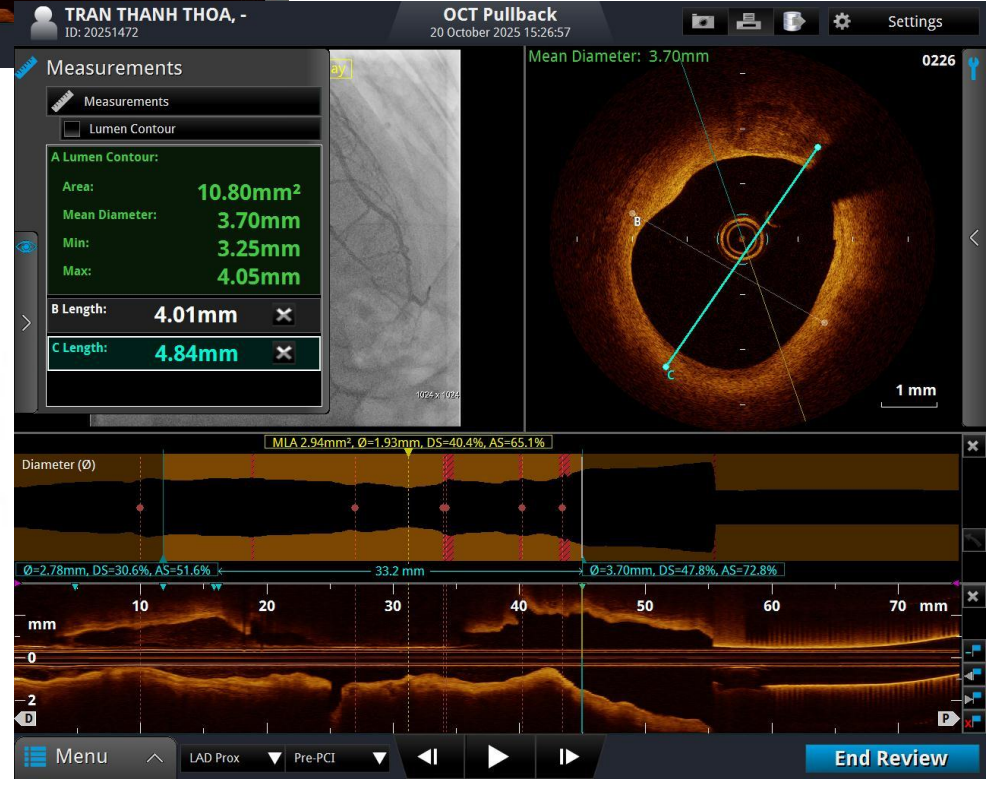
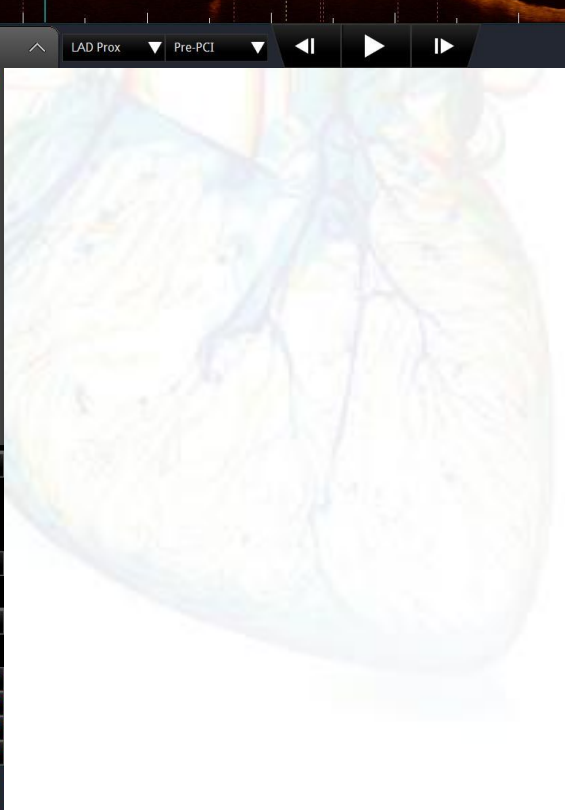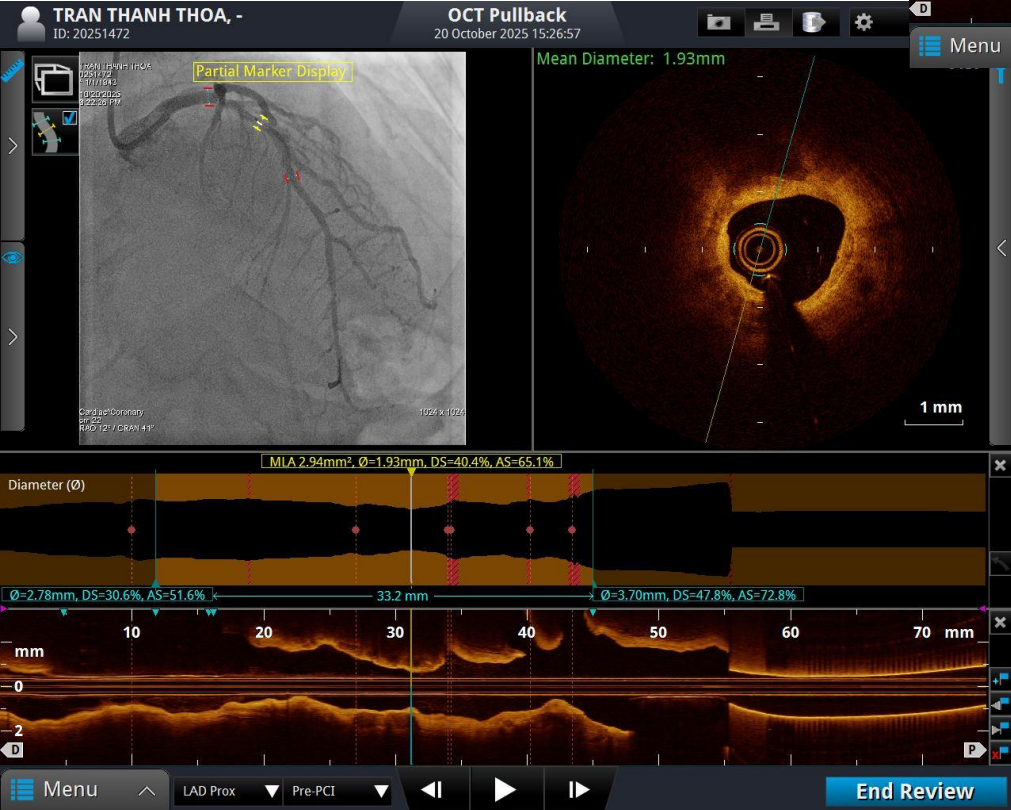
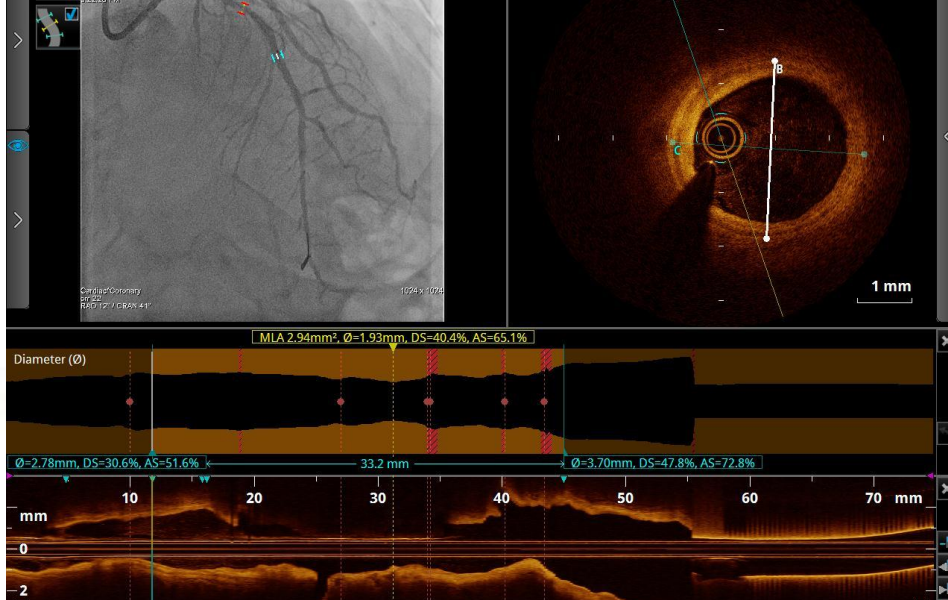
# Angiogram



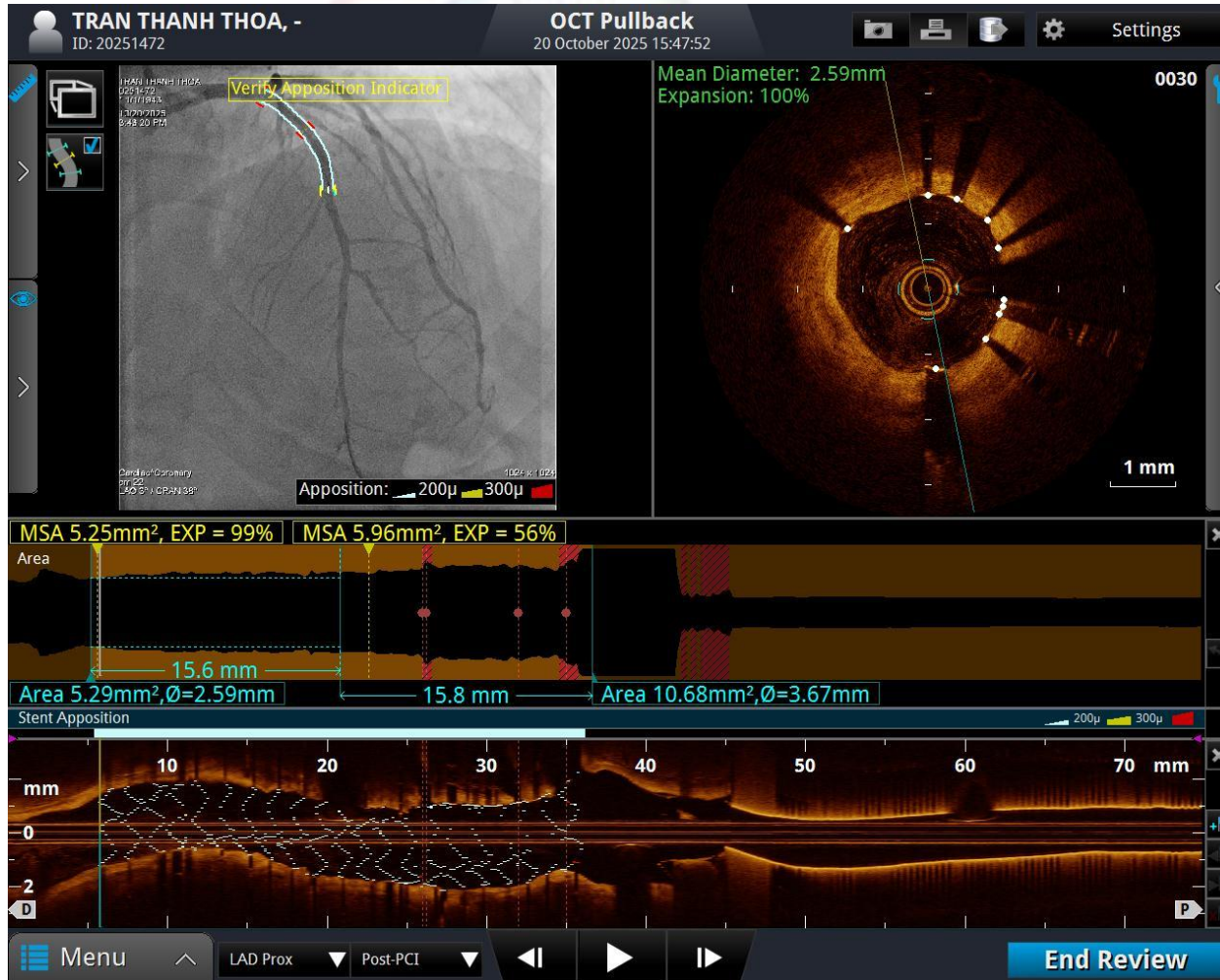
# Angiogram



# OCT MLD



# MAX



**Thank you for your attention !**

