



ASIC COFFEE CORNER

ThS.BS. Trần Minh Trung

Tổng Thư ký Hội Tim mạch và Tim mạch Can Thiệp

An Giang

Khoa Nội Tim Mạch – BVĐK Kiên Giang



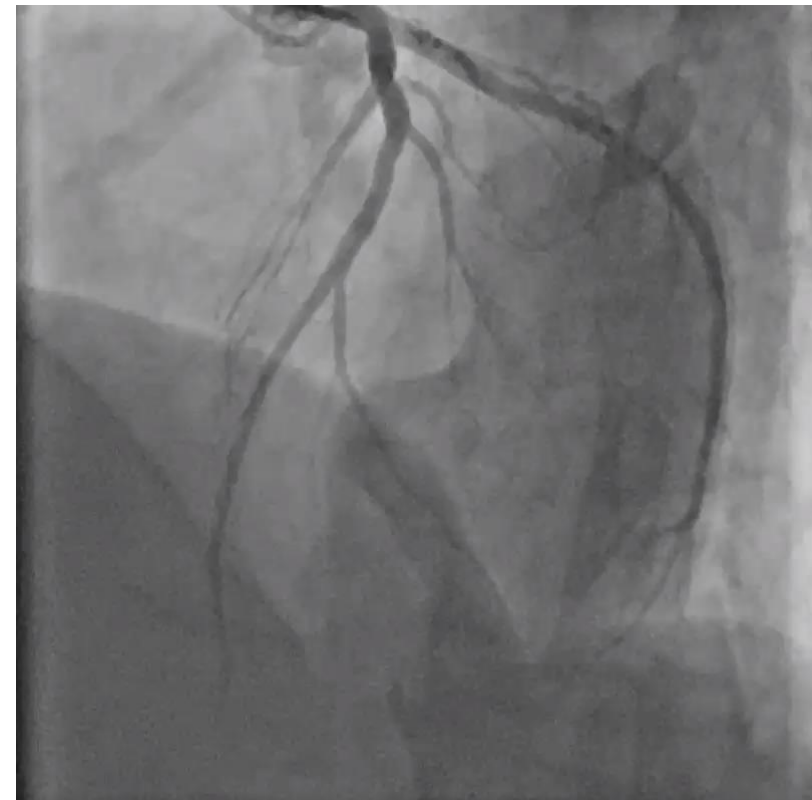
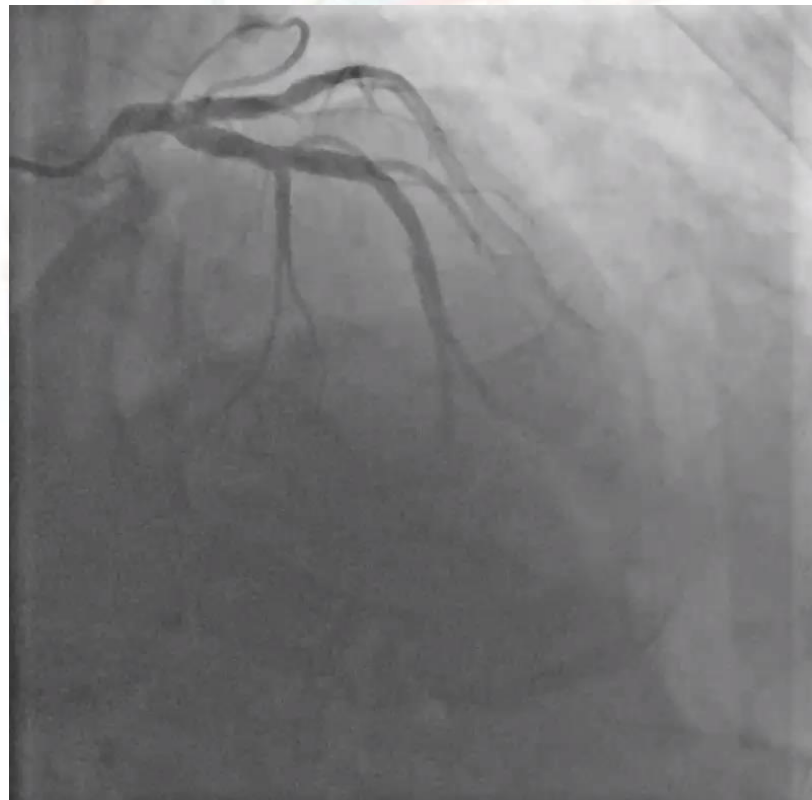
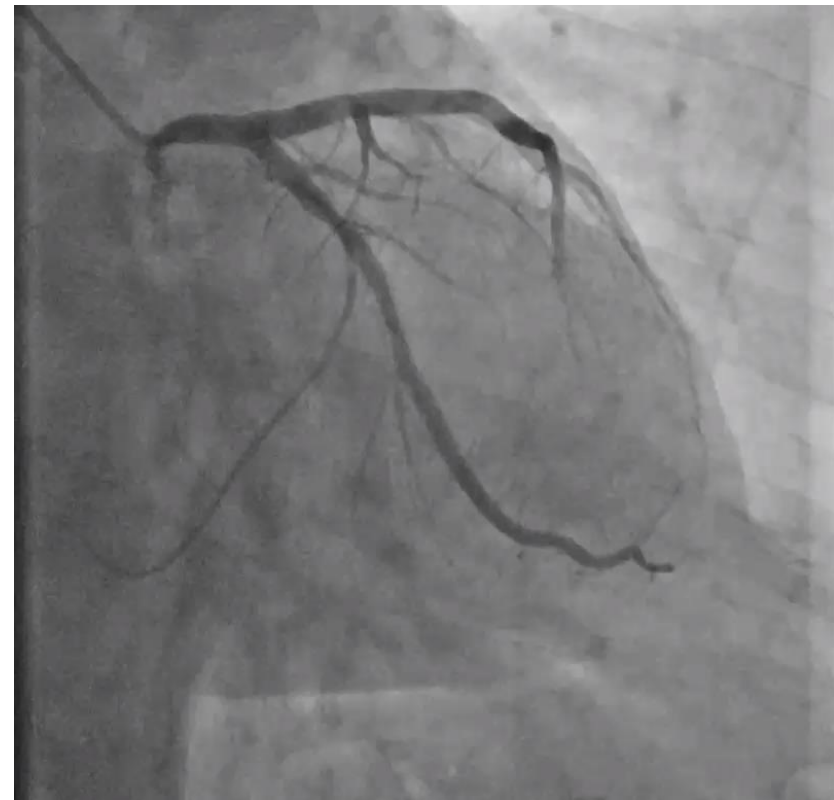Case TRAN M H

Lâm sàng

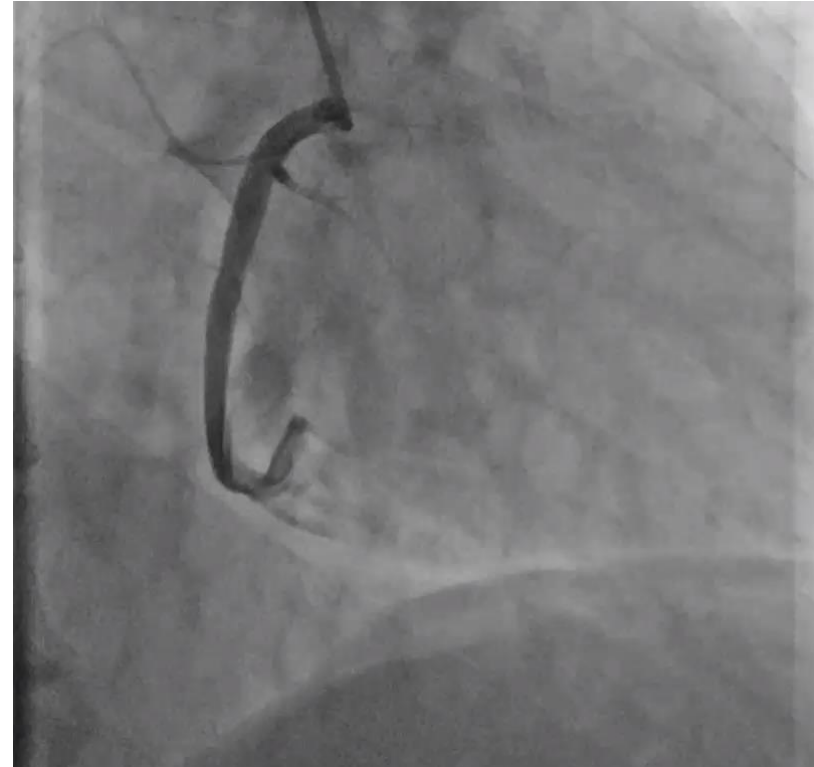
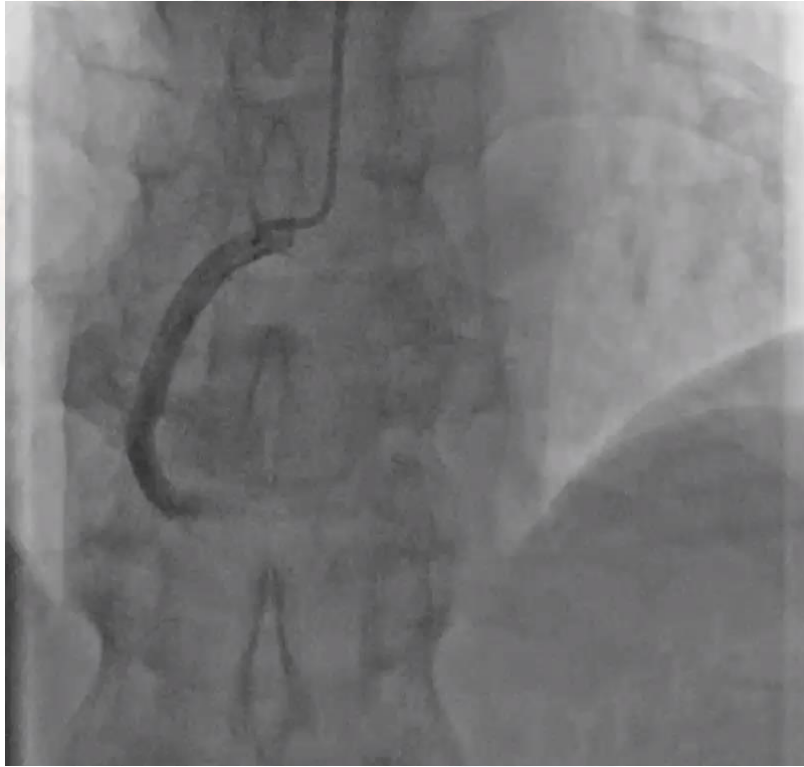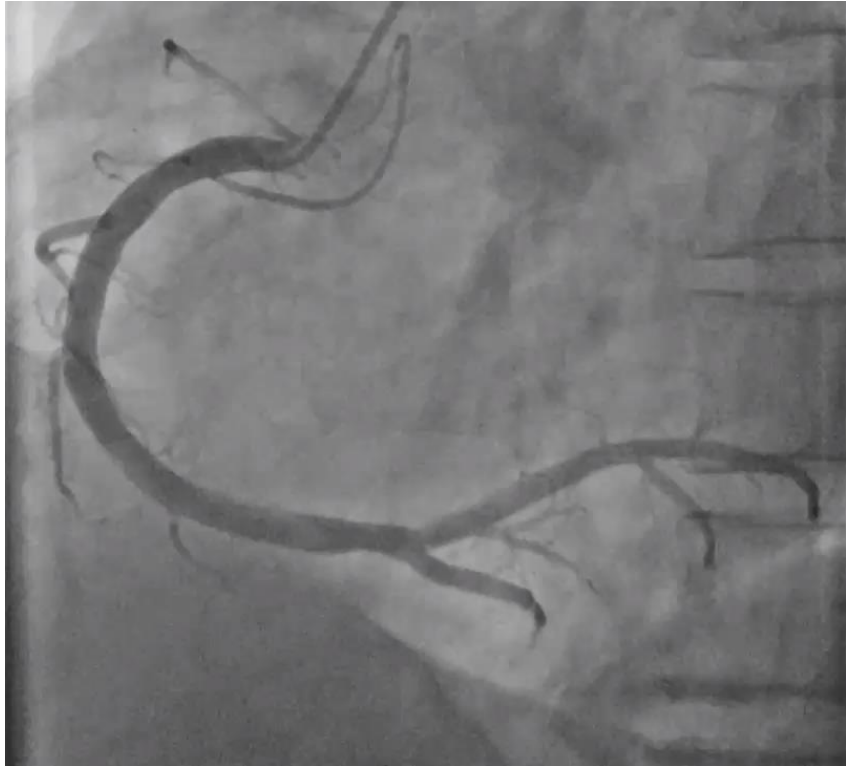An anatomical illustration of the human heart, showing the major blood vessels. A stent is visible in the left coronary artery, which is highlighted in blue. The heart is shown in a slightly transparent, light blue color, allowing the underlying structures to be seen.

- Bệnh nhân: nam, 63 tuổi
- Nhập viện vì đau thắt ngực
- Chẩn đoán: **NSTEMI**
- Tiền căn: Hút thuốc lá, THA, BMV đã đặt stent LCx (2023)

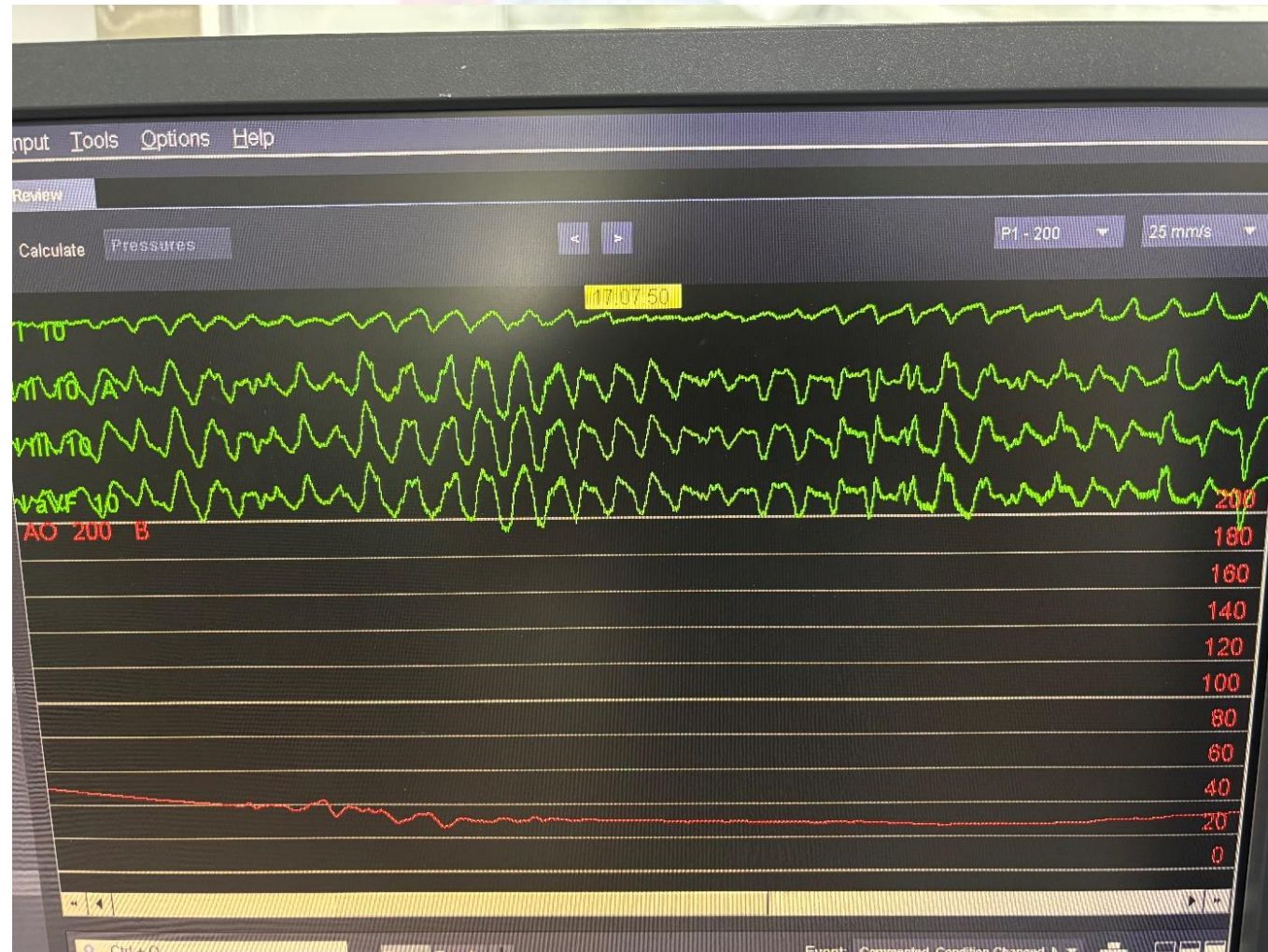Angiogram



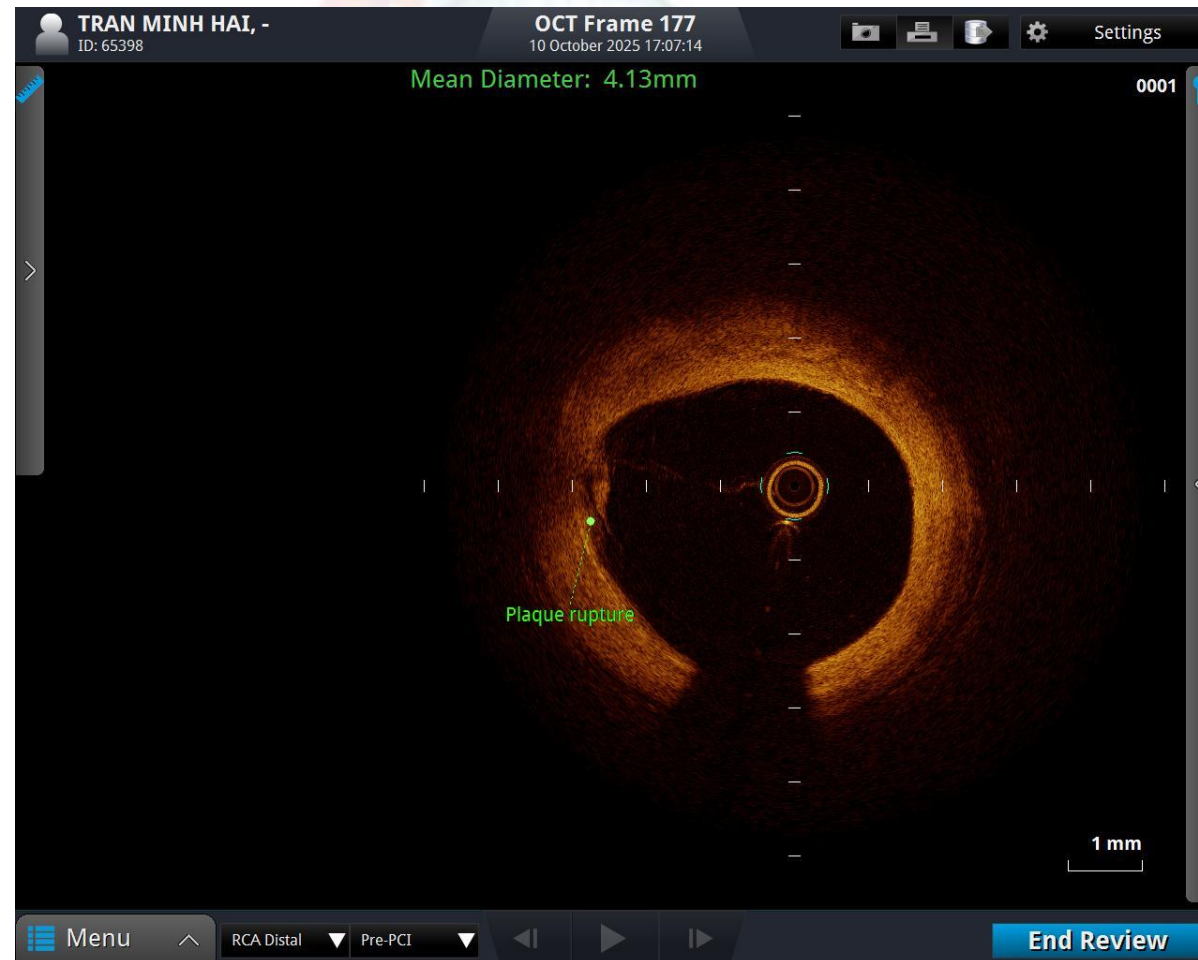
Angiogram



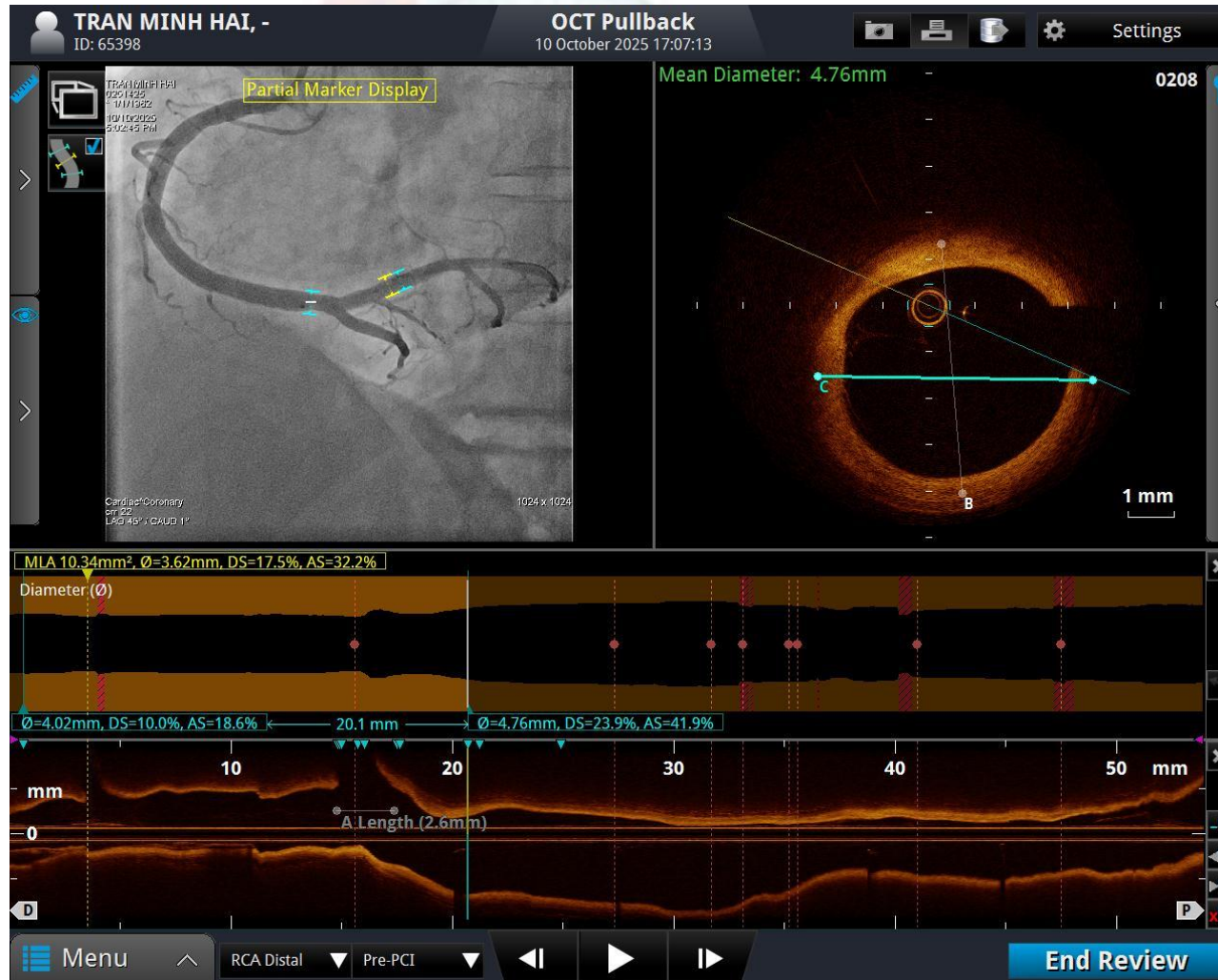
Pre PCI OCT RCAIII



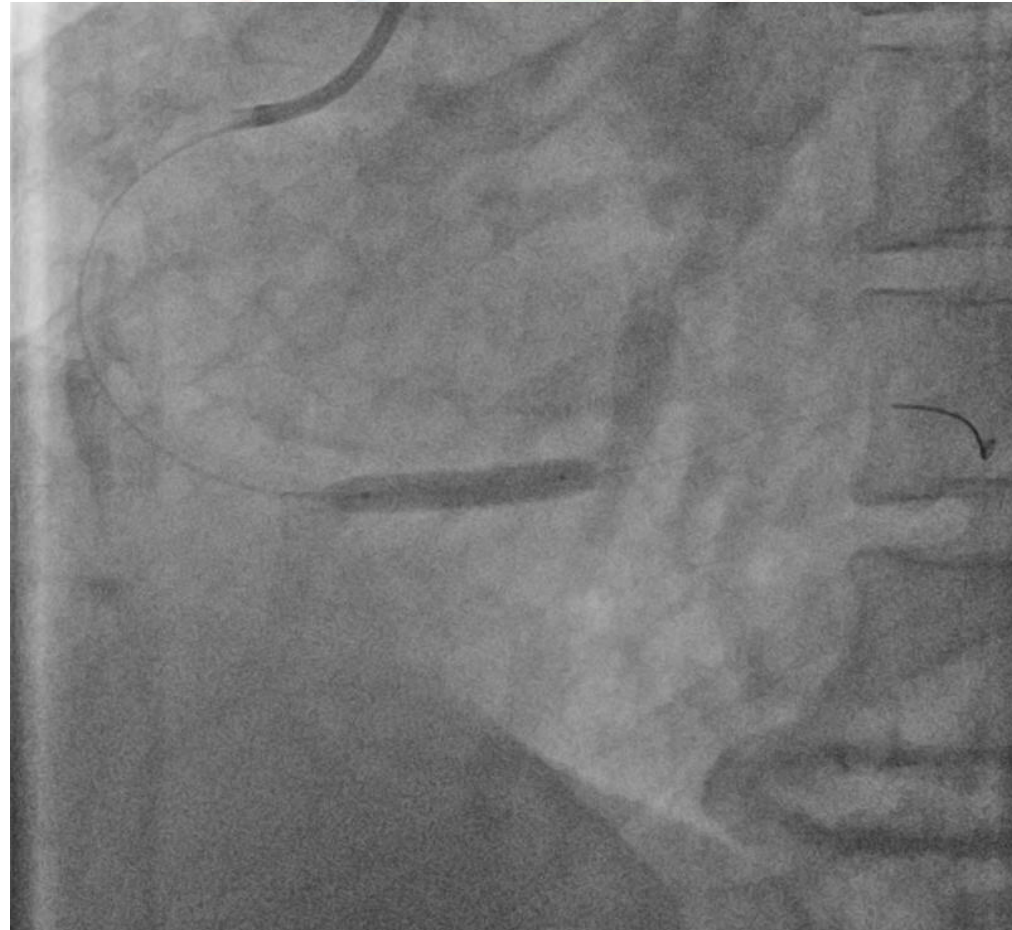OCT Finding



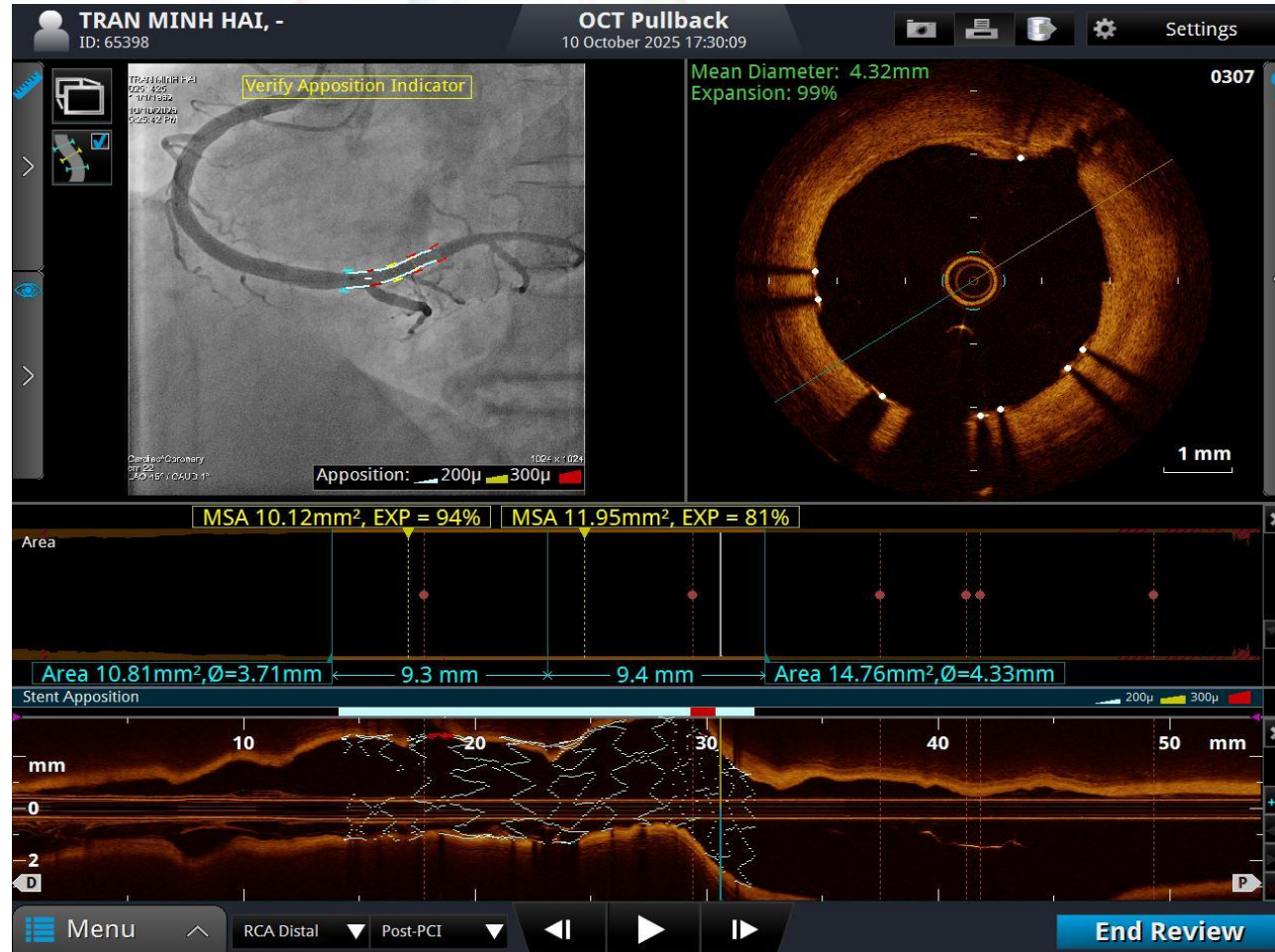
MLD



DES 4.0*19mm, 14atm-4.42, Post
dilatatation 4.5*10mm NC Balloon



MAX



Thank you for your attention !

