



CASES REPORT

Hội chứng vành cấp dưới góc nhìn OCT


Bs Nguyễn Minh Hoàng
Ths. Bs. Trần Minh Trung



2025 ACC/AHA GUIDELINE FOR ACS

OCT IS NOW CLASS 1A

Recommended in patients with acute coronary syndromes undergoing coronary stent implantation in left main artery or in complex lesions



CA LÂM SÀNG

- Nam, 65 tuổi
- V/v vì: nặng ngực từng cơn sau xương ức khoảng 21 giờ, vã mồ hôi
- Tiền sử: THA
- Lúc nhập viện: bệnh tỉnh, niêm hồng, sinh hiệu ổn, giảm nặng ngực, nằm đầu ngang, không phù, tim đều rõ, phổi trong, bụng mềm.
- ECG: nhịp xoang đều, tần số 60 lần/phút, phì đại thất trái, ST chênh lên ở V1-V4, sóng T hai pha ở V1-V4.
- Siêu âm tim: Dày đồng tâm thất trái, EF 30%, giảm động vách liên thất mỏng, không hẹp hở van tim, không dịch màng ngoài tim

CA LÂM SÀNG

Kết quả xét nghiệm:

Troponin I hs: >250000 pg/mL (mẫu 0h)

Cholesterol toàn phần: 5.23 mmol/L

LDL-C: 3.77 mmol/L

HDL-C: 1.09 mmol/L

Triglycerid: 1.85 mmol/L

Creatinin máu: 102 umol/L

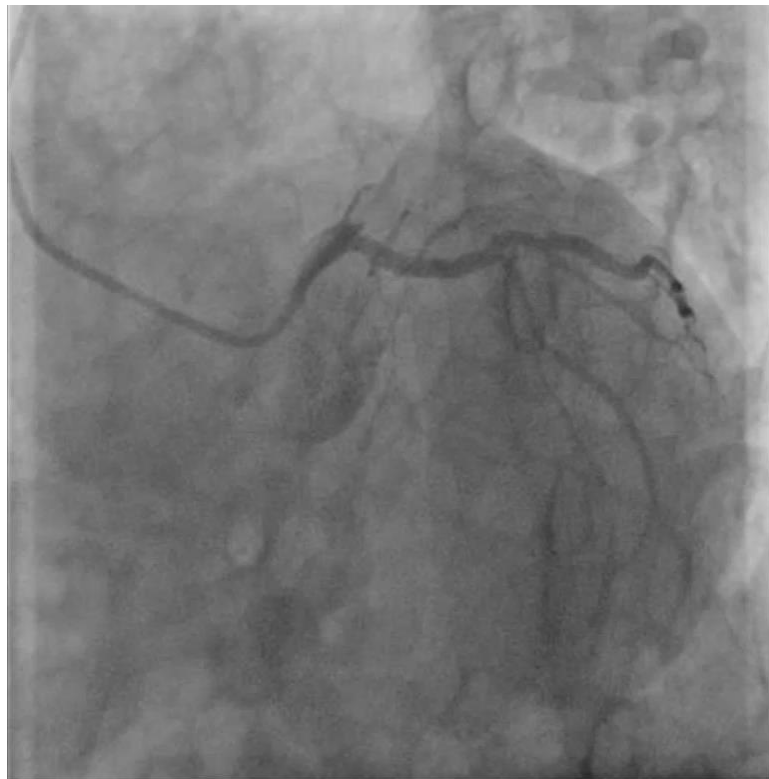Hb: 12.7 g/dL

PLT: 310 G/L

WBC 10.2 G/L

→ Chẩn đoán sơ bộ: Nhồi máu cơ tim cấp ST chênh lên trước vách mỏng giờ thứ 21 biến chứng suy tim cấp (EF 30%)/ THA

CHỤP ĐỘNG MẠCH VÀNH

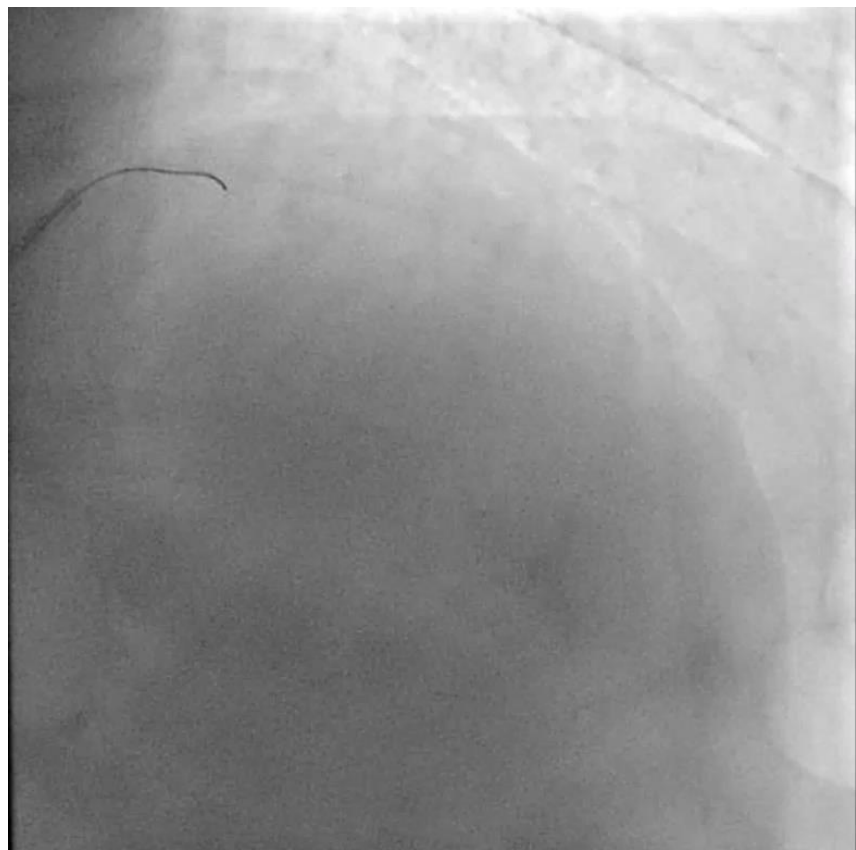


LMCA: Không hẹp

LAD: Tắc LAD I+ huyết khối(+++)

LCx: Thâm nhiễm OM1

RCA: Hẹp 70% RCA II



THÔNG ĐIỆP

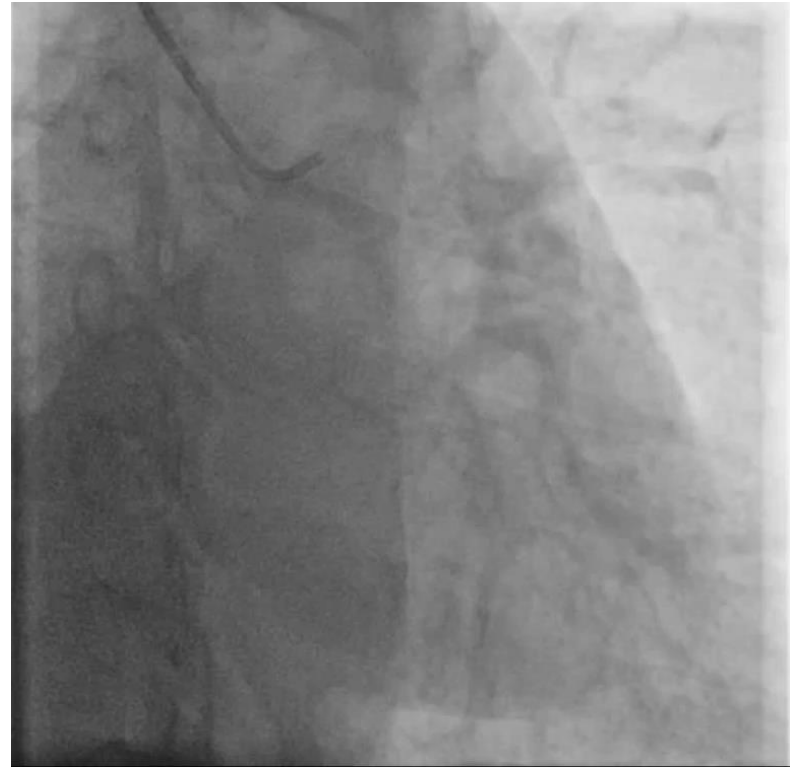
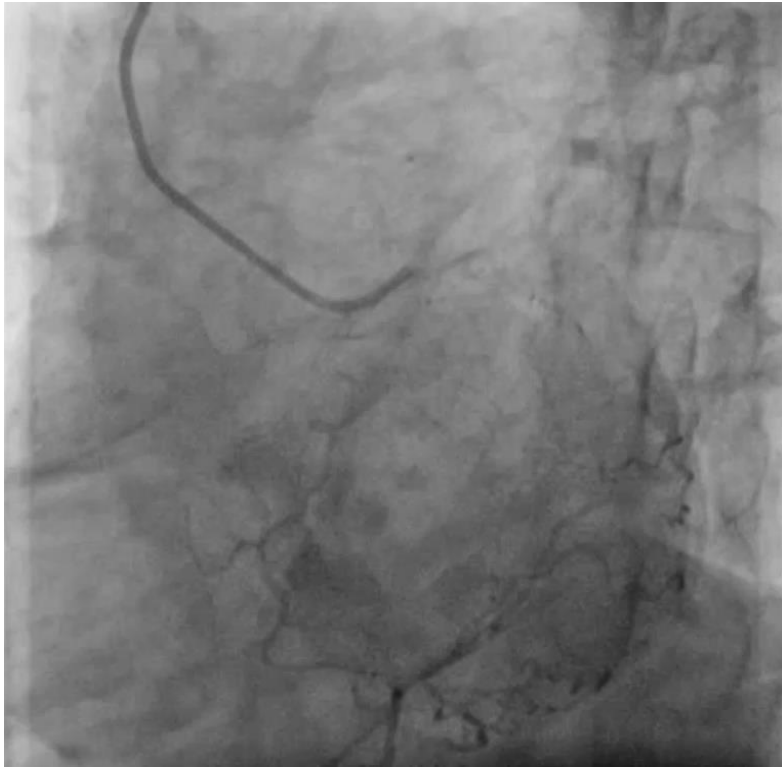- OCT hướng dẫn can thiệp giúp tối ưu hóa sizing stent, xác định chiều dài bao phủ, và đánh giá kết quả sau can thiệp
- Cá thể hóa điều trị dựa trên đặc điểm mảng xơ vữa là chìa khóa thành công trong can thiệp mạch vành phức tạp

CA LÂM SÀNG 2

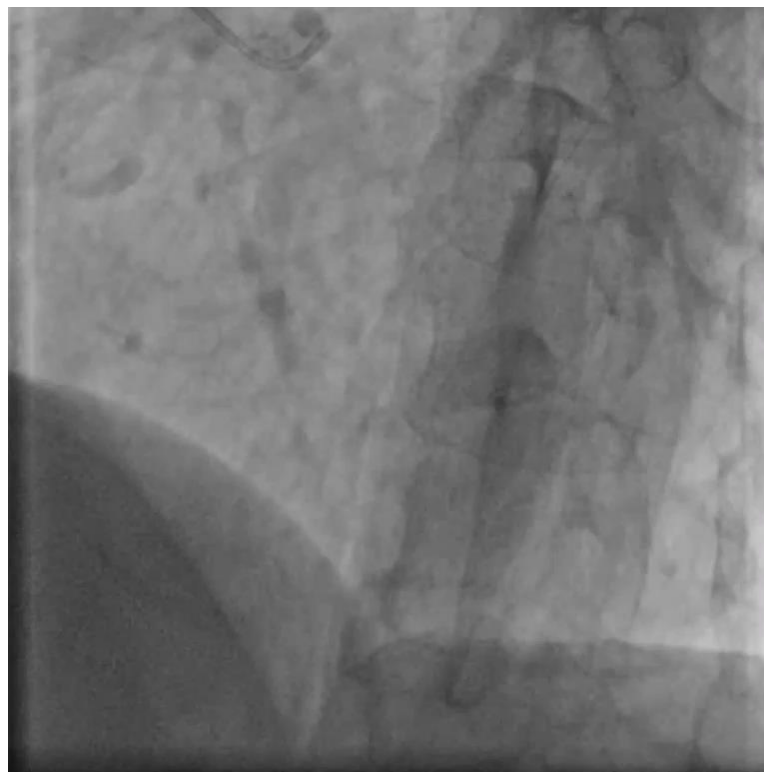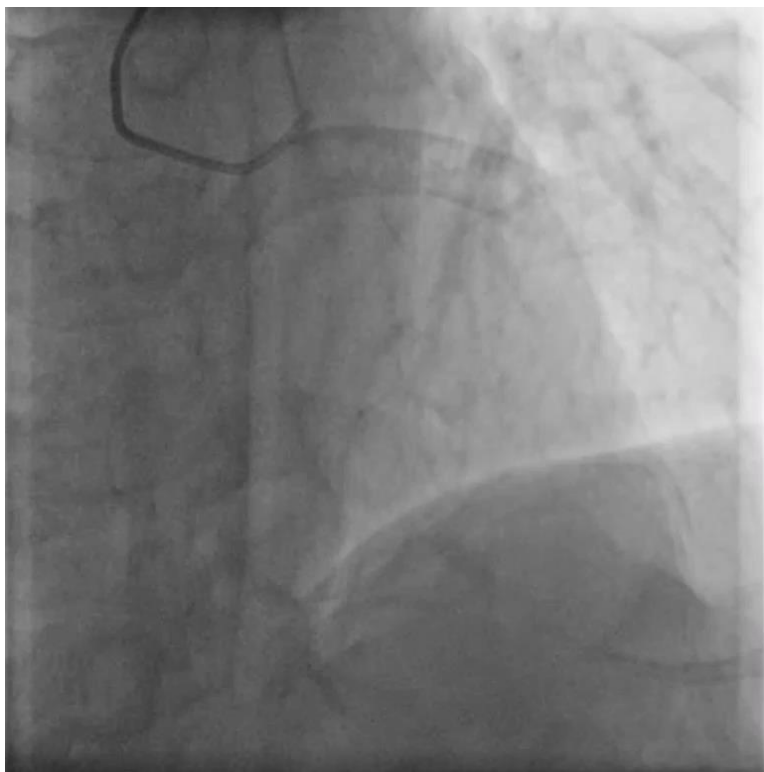
- Nam, 66 tuổi
- V/v vì: nặng ngực từng cơn sau xương ức khoảng 1 tuần nay, mỗi cơn kéo dài khoảng 20 phút, tăng dần về cường độ.
- Tiền sử: THA
- Lúc nhập viện: bệnh tỉnh, niêm hồng, sinh hiệu ổn, giảm nặng ngực, nằm đầu ngang, không phù, tim đều rõ, phổi trong, bụng mềm.
- ECG: nhịp xoang đều, tần số 88 lần/phút, T hai pha ở V1-V4.
- Siêu âm tim: trong giới hạn bình thường
- Xét nghiệm: Troponin I hs, CTM, ure, creatinin, điện giải đồ, AST, ALT, bộ mỡ trong giới hạn bình thường.

→ Chẩn đoán sơ bộ: Đau thắt ngực không ổn định/ THA

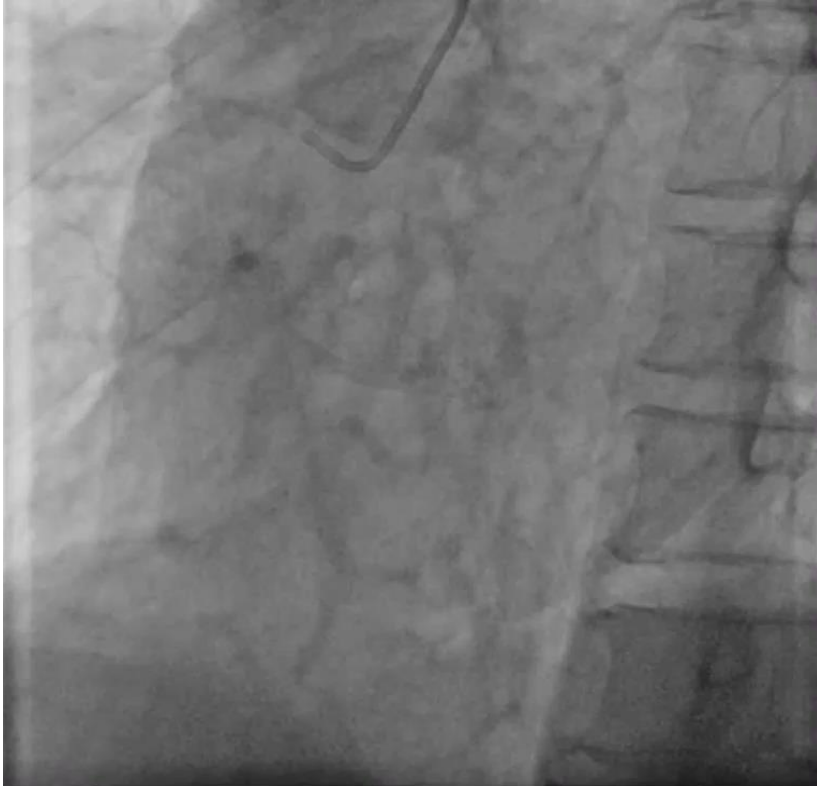CHỤP ĐỘNG MẠCH VÀNH



CHỤP ĐỘNG MẠCH VÀNH



CHỤP ĐỘNG MẠCH VÀNH



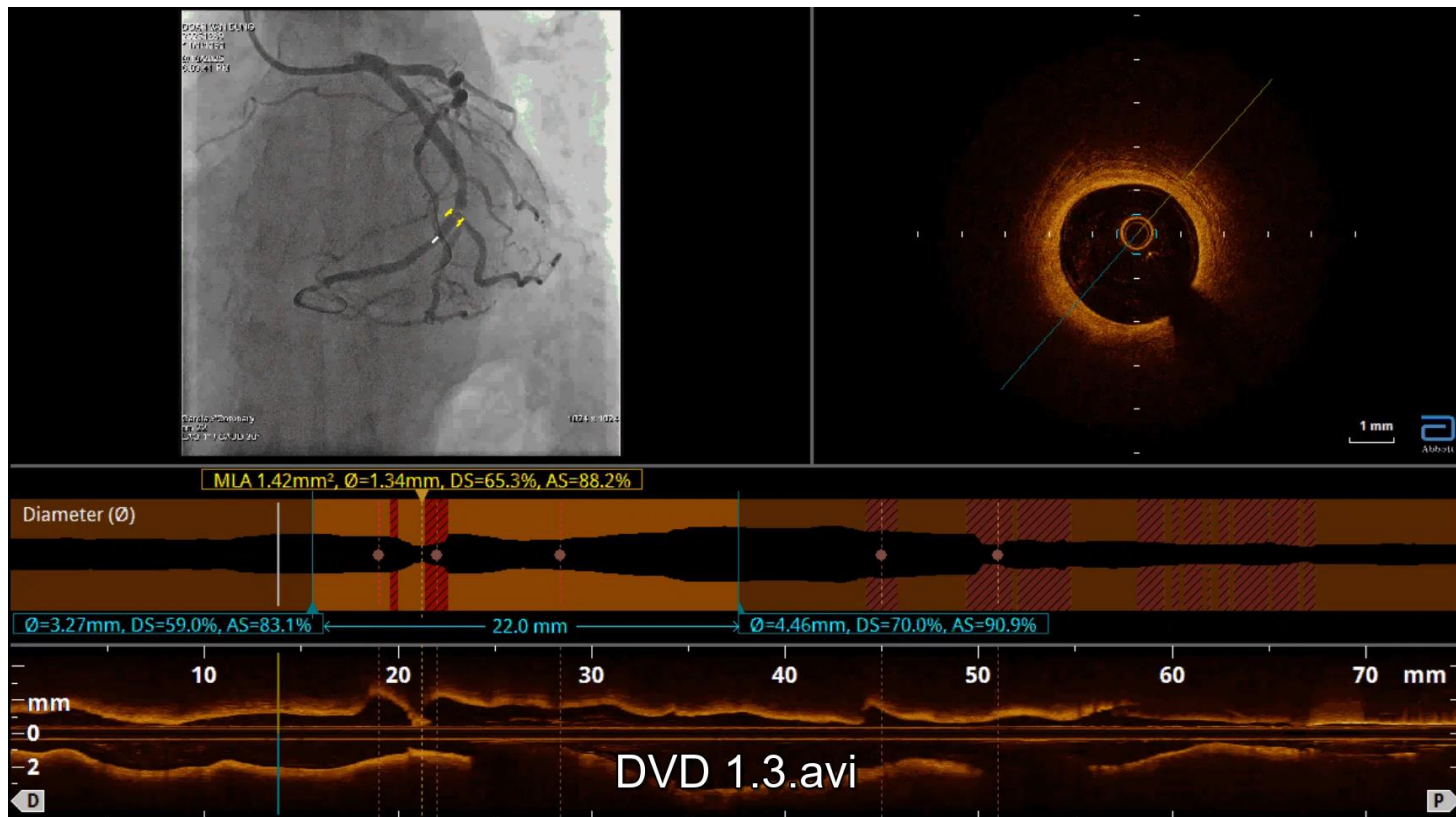
LMCA: Không hẹp

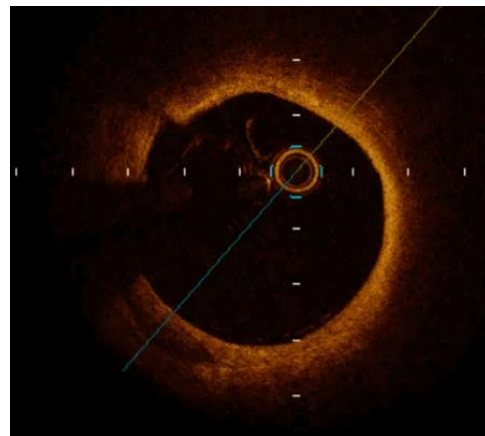
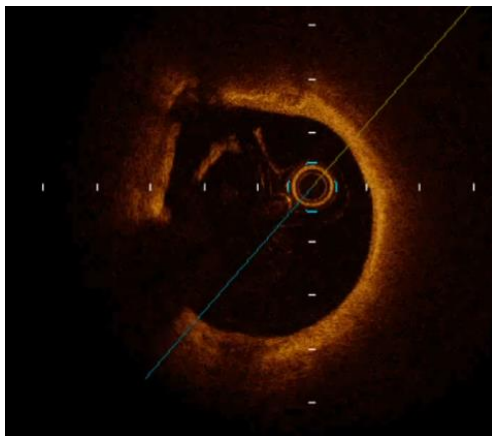
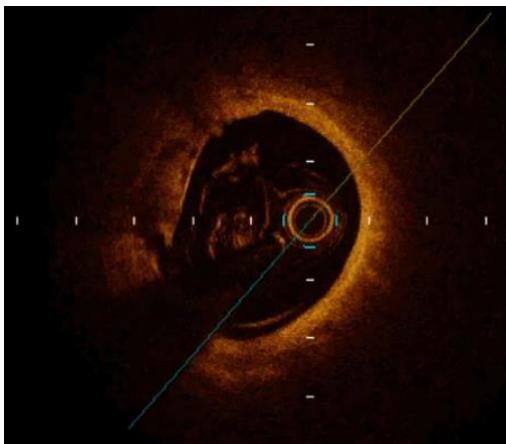
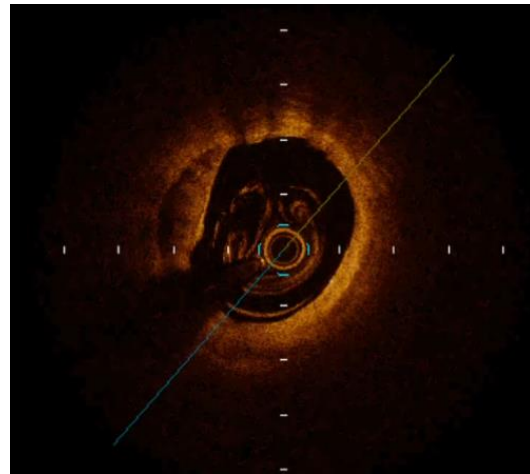
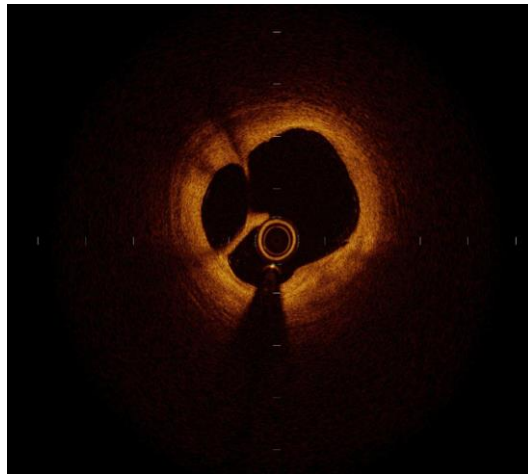
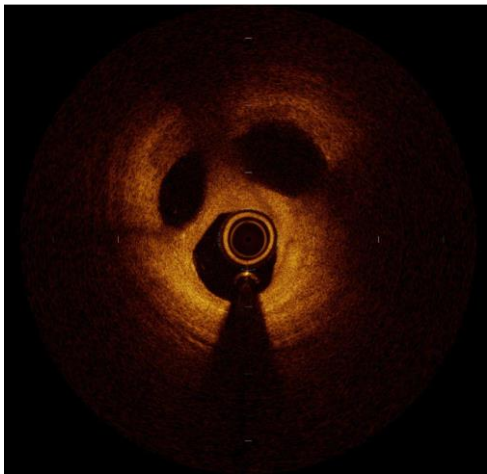
LAD: Hẹp 70% LAD II

LCx: Hẹp 90% LCx II

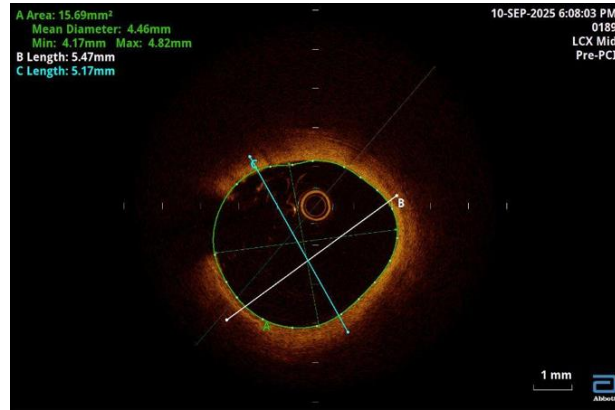
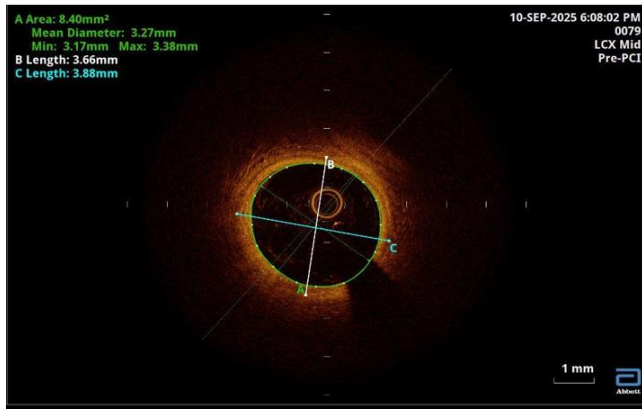
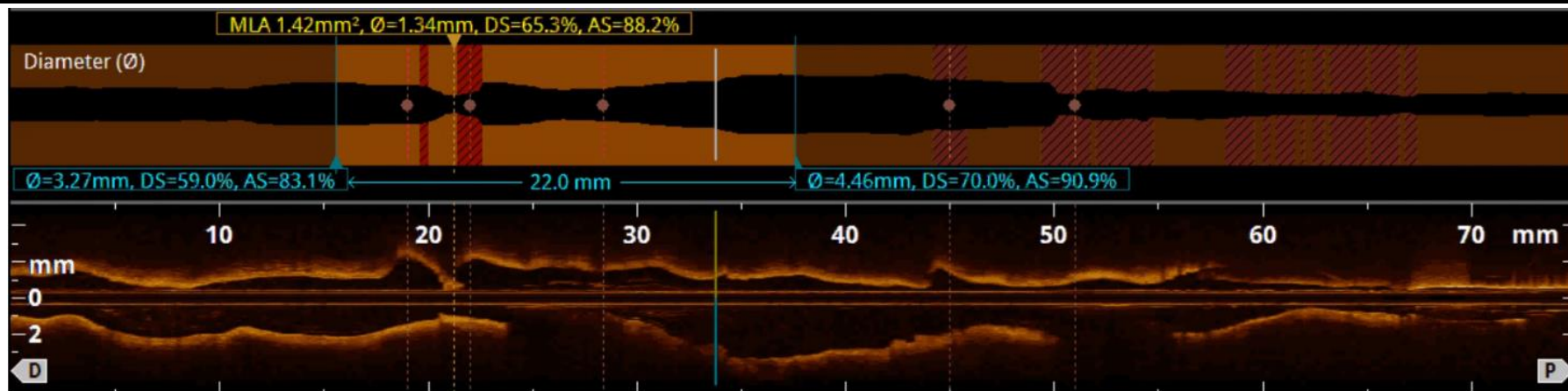
RCA: Thiếu sản

OCT LCx Pre-PCI

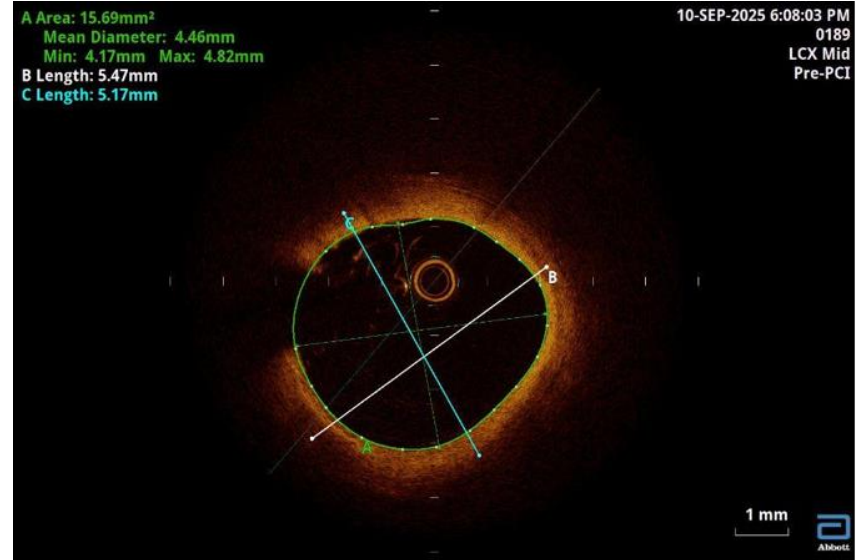
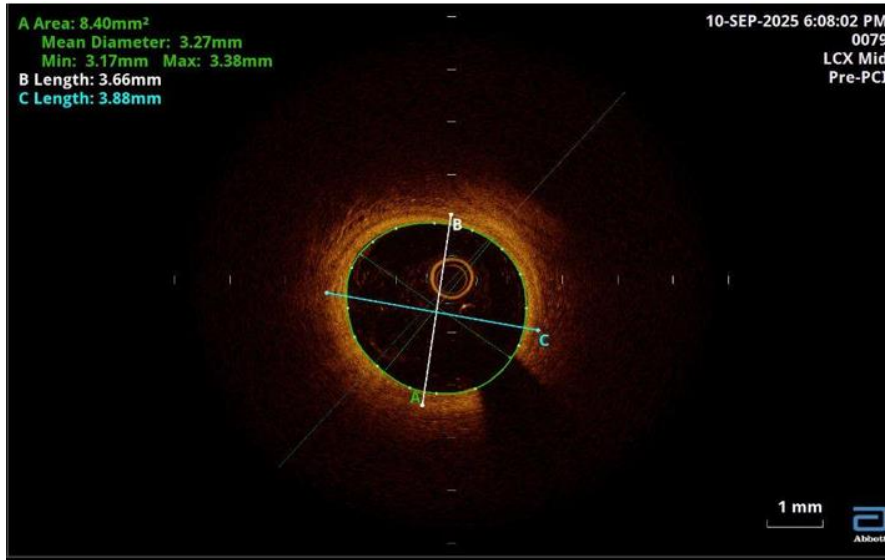




Length – select landing zone



Diameter



DOAN VAN DANG
2025/09/10
11:01:59
9/10/2025
9:02:41 PM


Cardiac/Coronary
am 22
LXG 11 / CAUD 30°

1024 x 1024

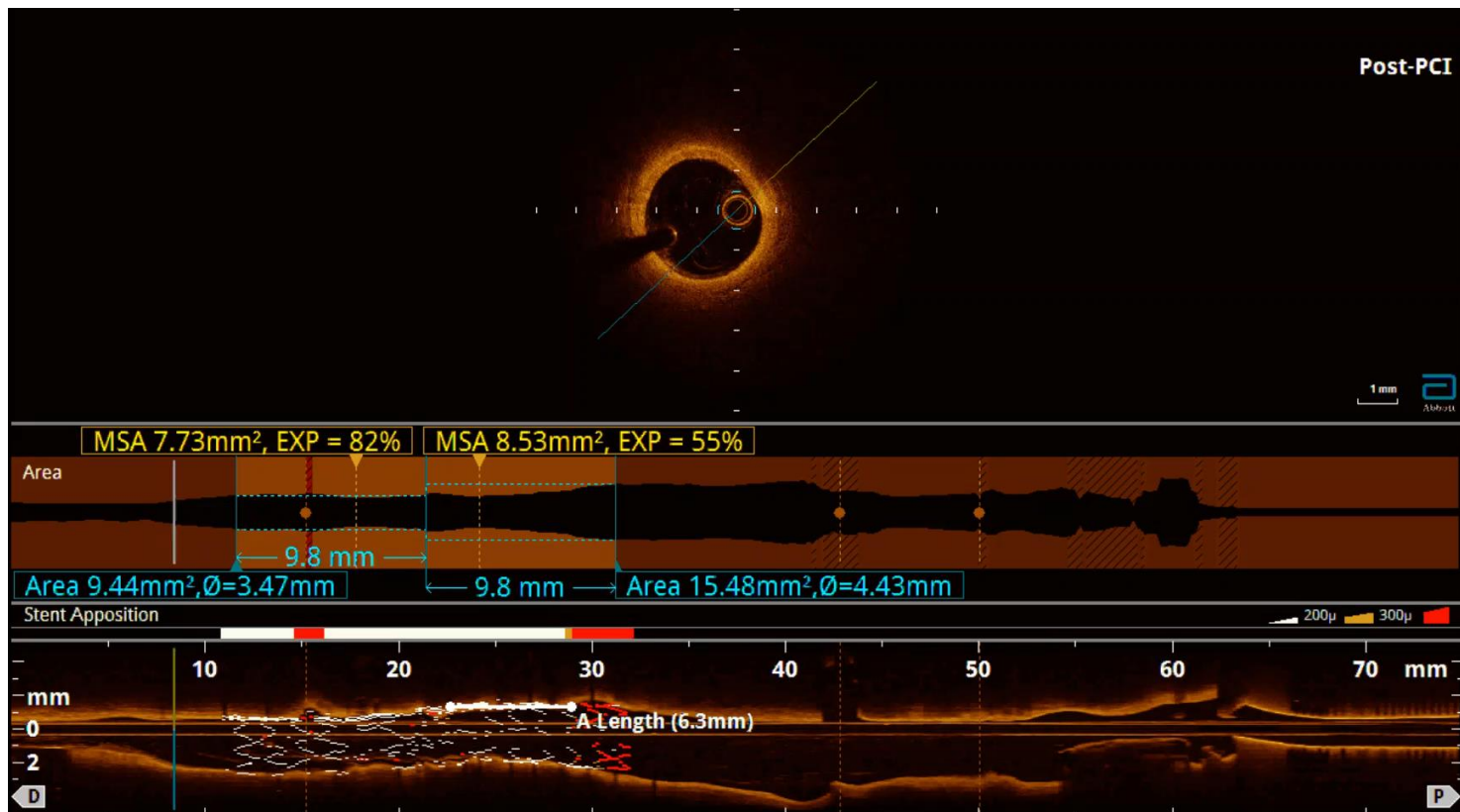
A Area: 7.06mm²
Mean Diameter: 2.97mm
Min: 2.47mm Max: 3.41mm

10-SEP-2025 6:08:02 PM
0095
LCX Mid
Pre-PCI

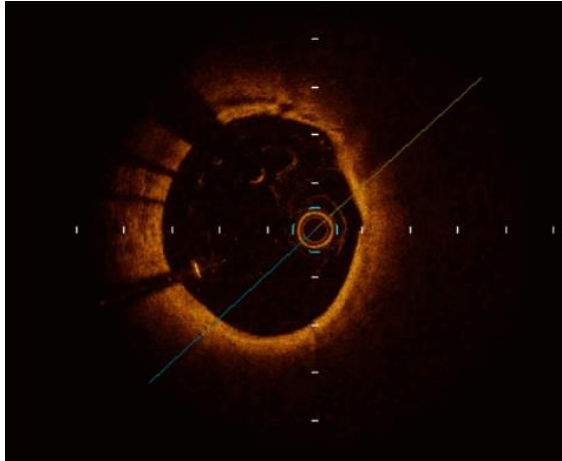
1 mm



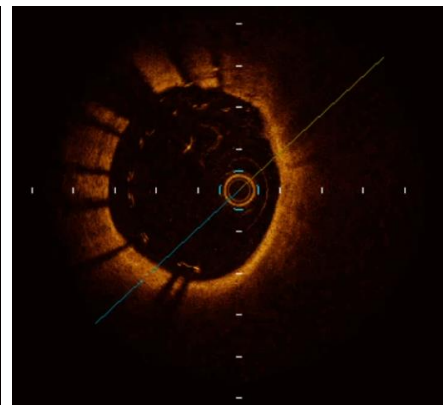
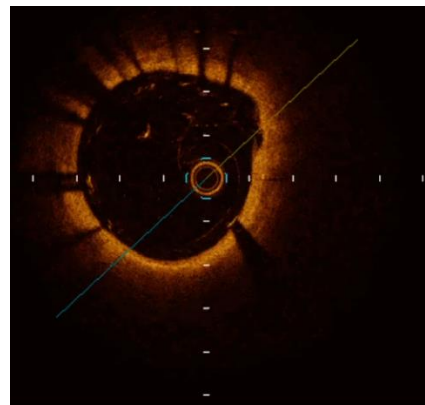
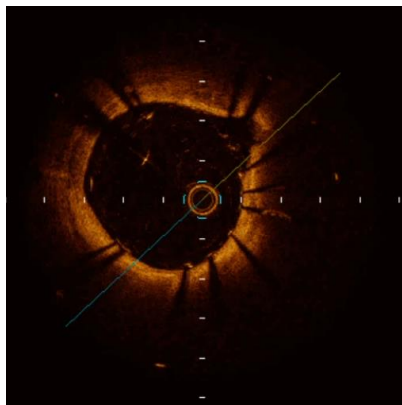
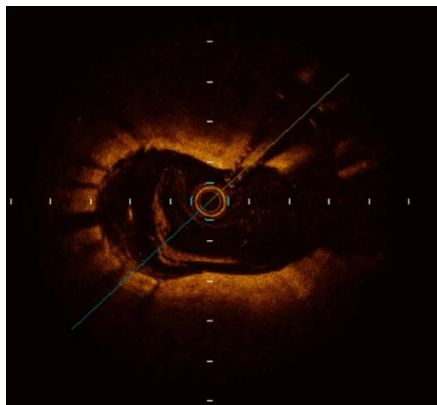
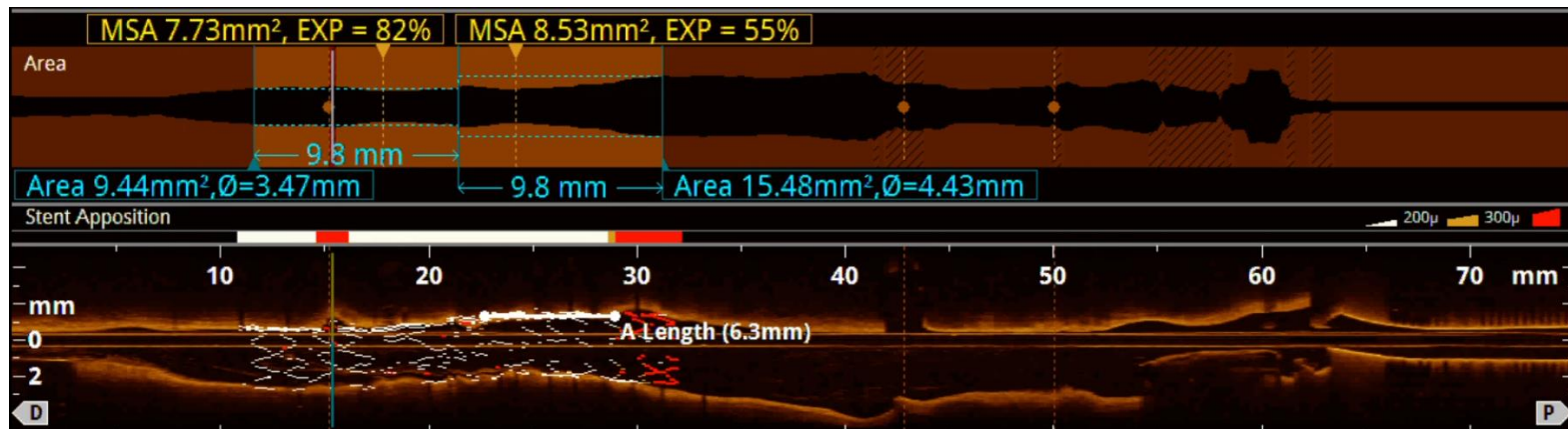
OCT LCx Post-PCI



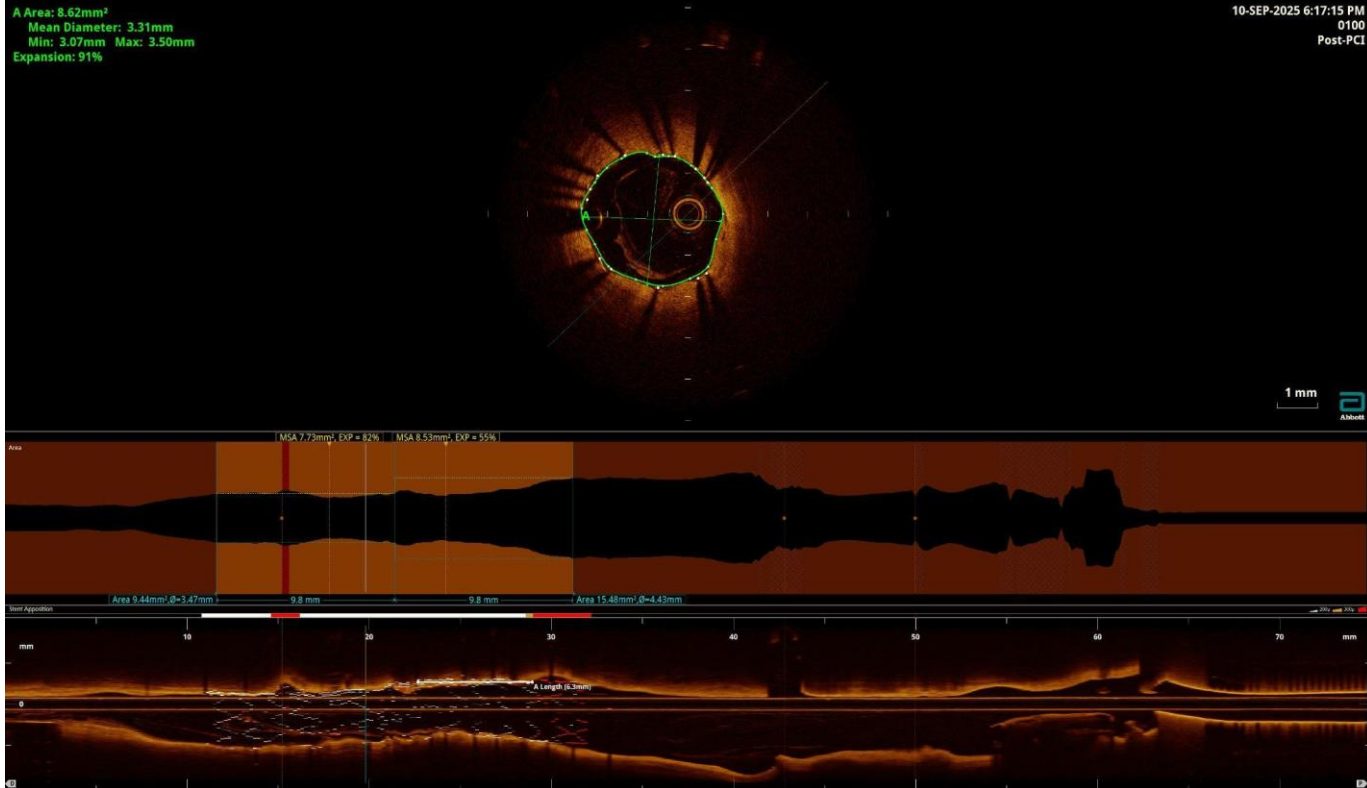
Medial dissection



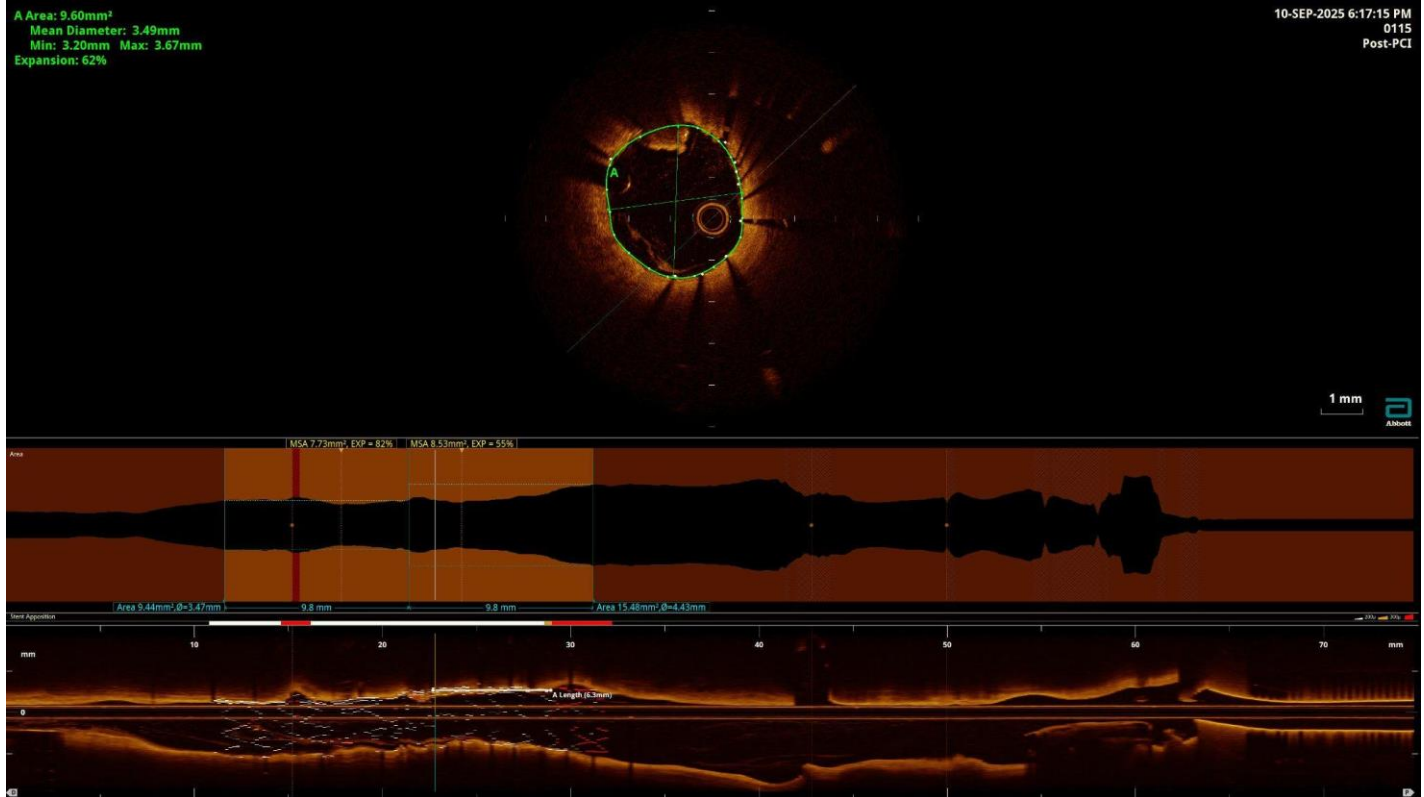
Apposition



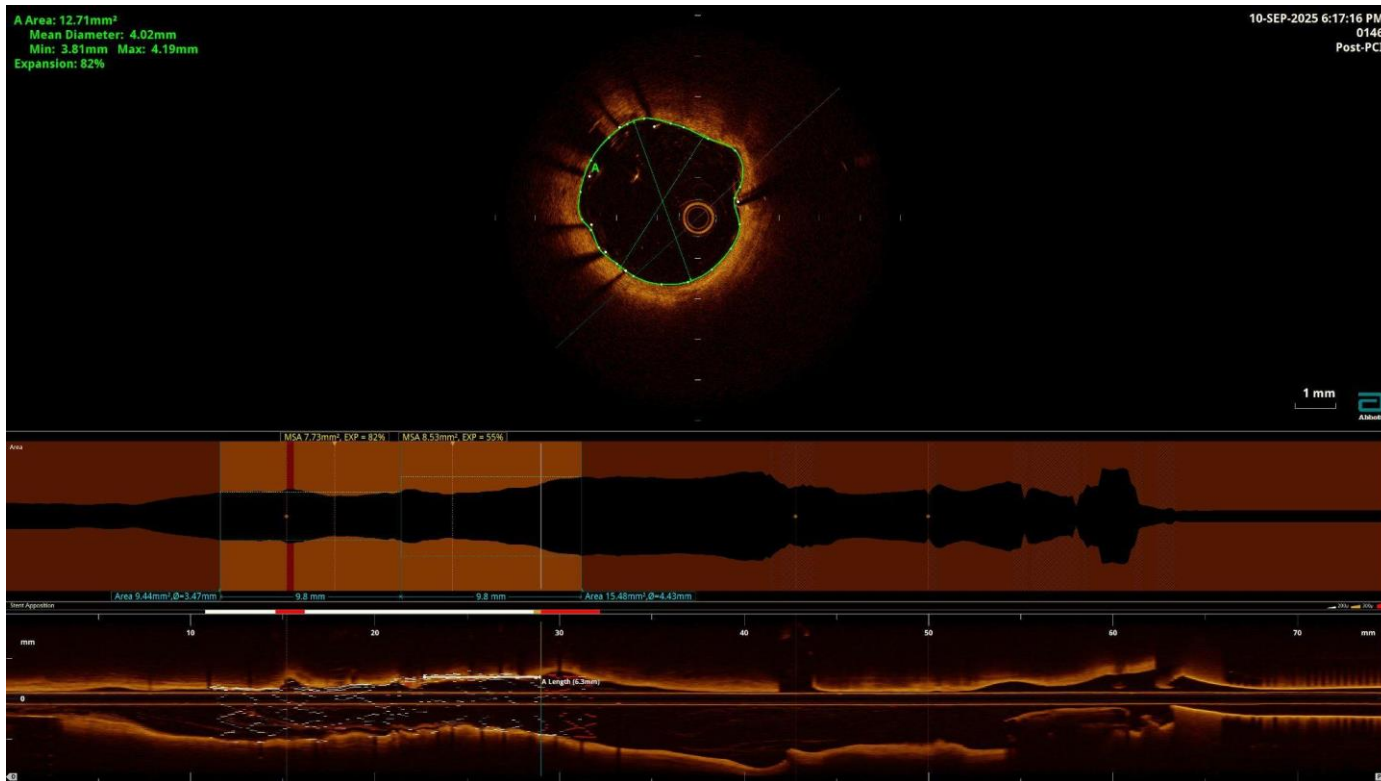
Xpansion



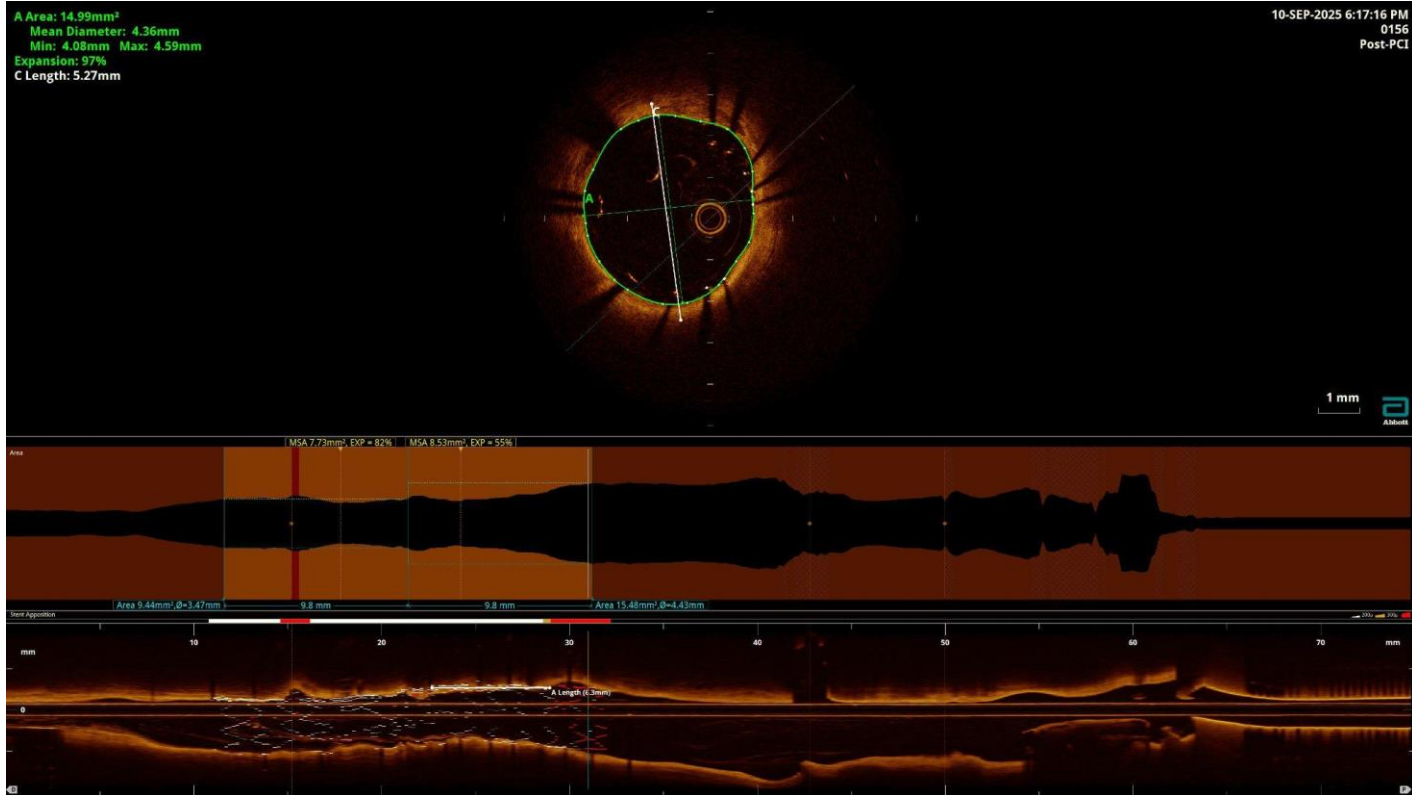
Xpansion



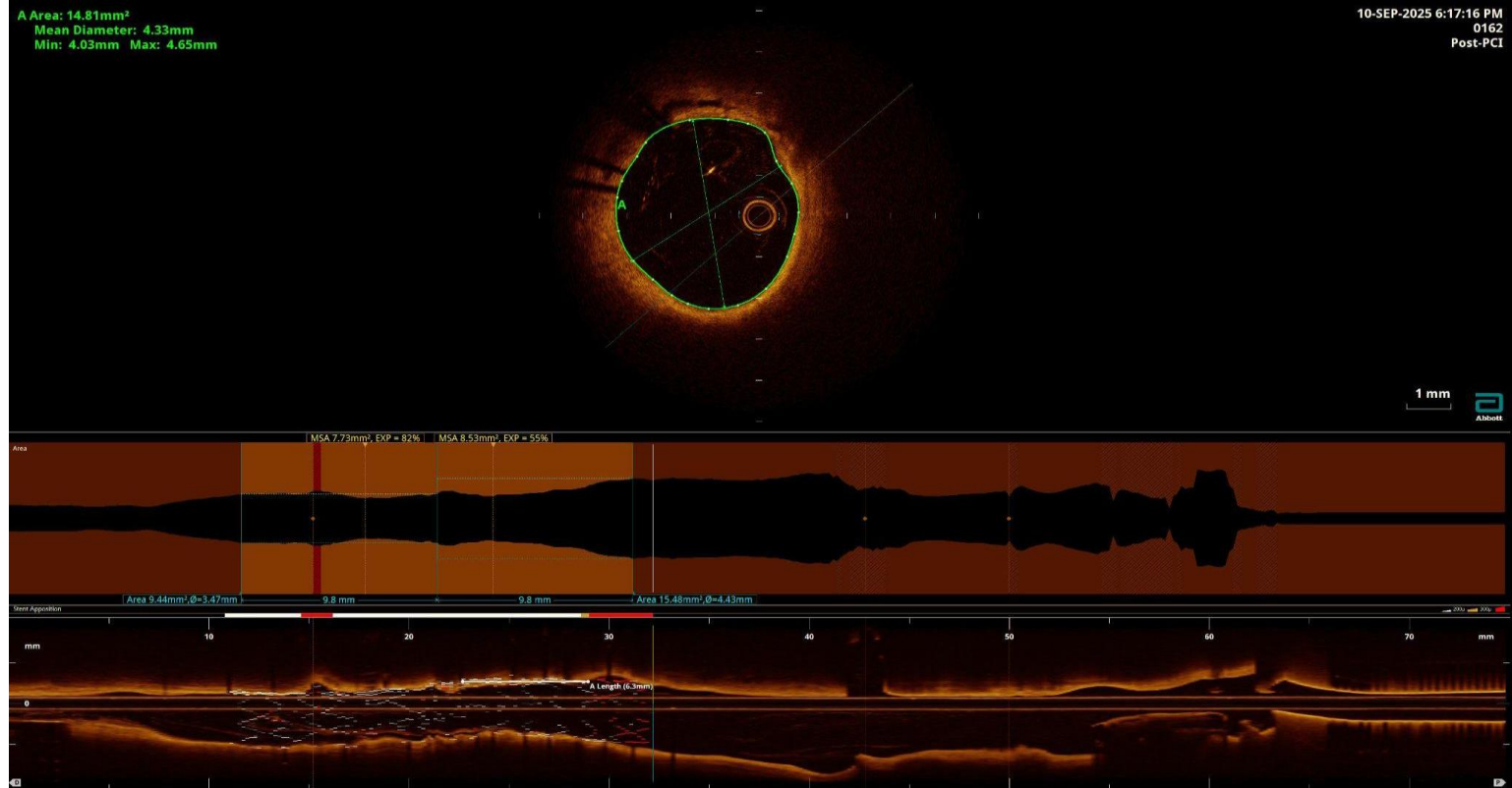
Xpansion



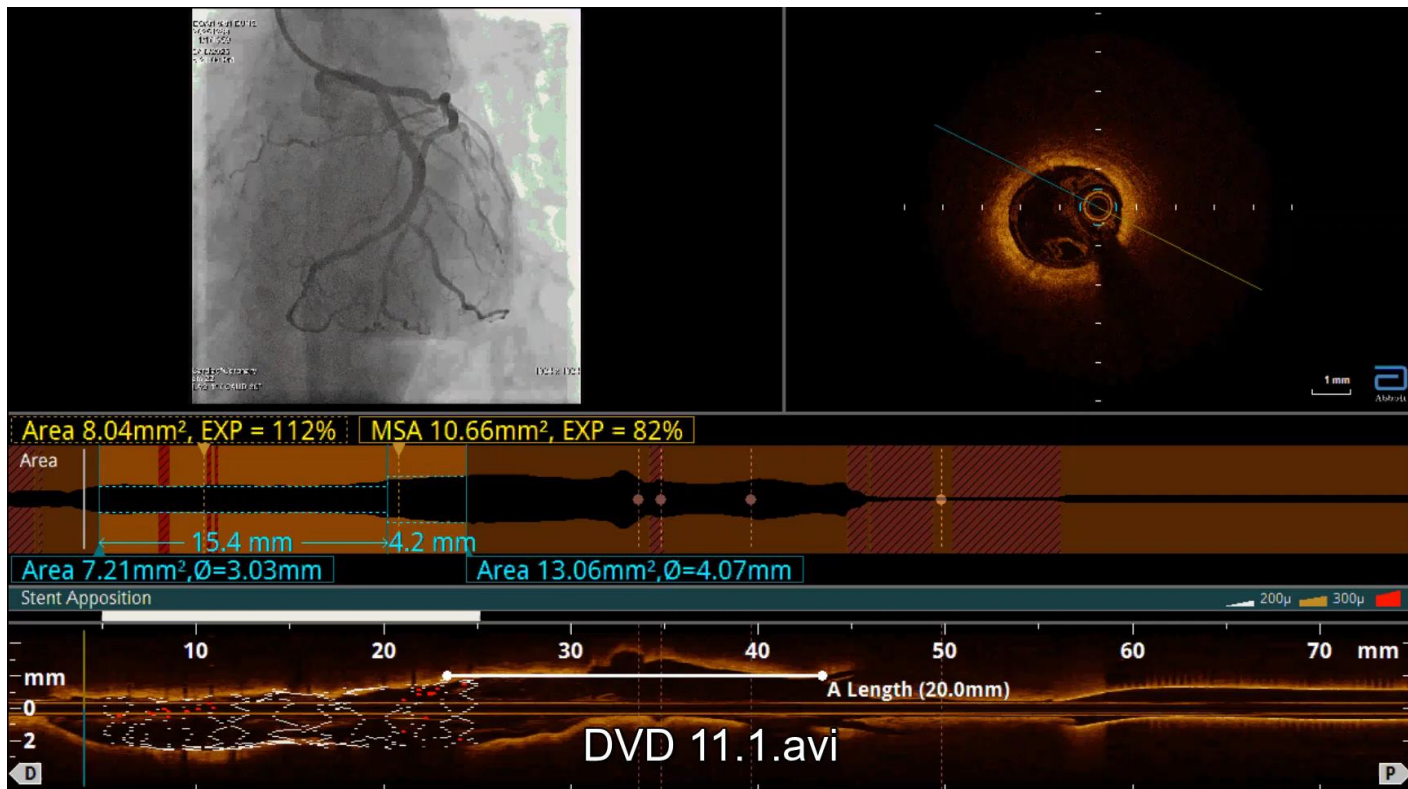
Xpansion



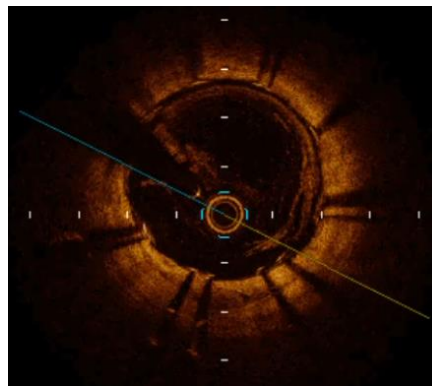
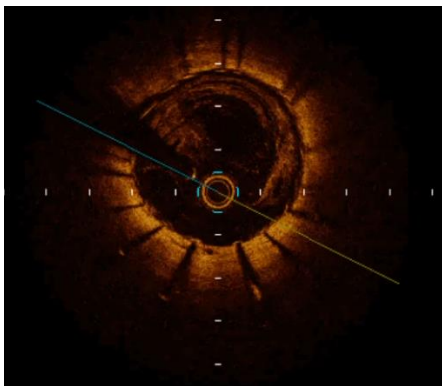
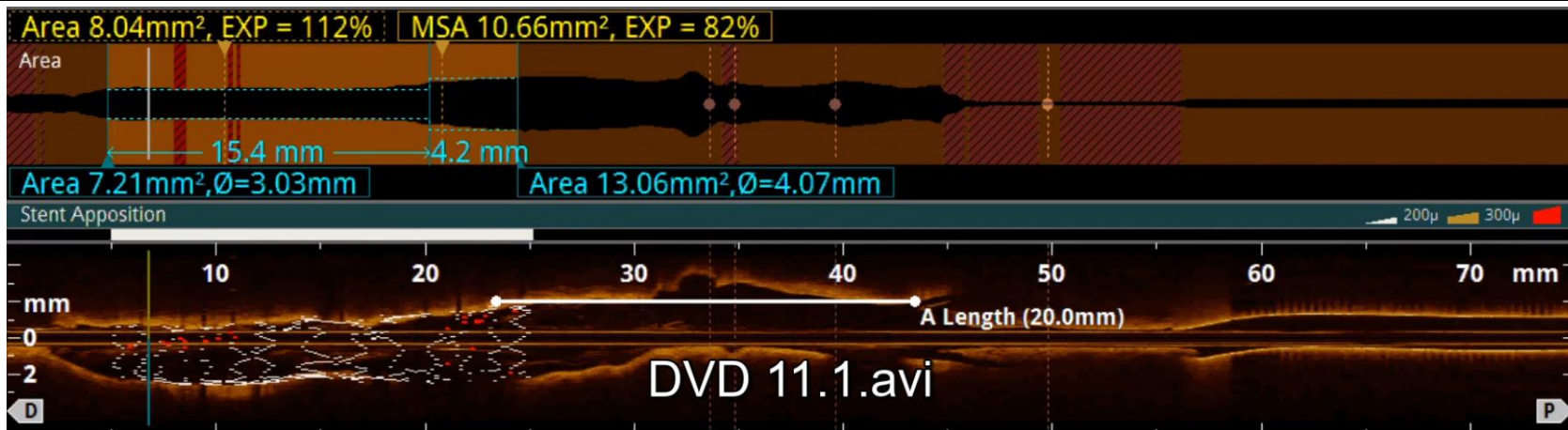Xpansion



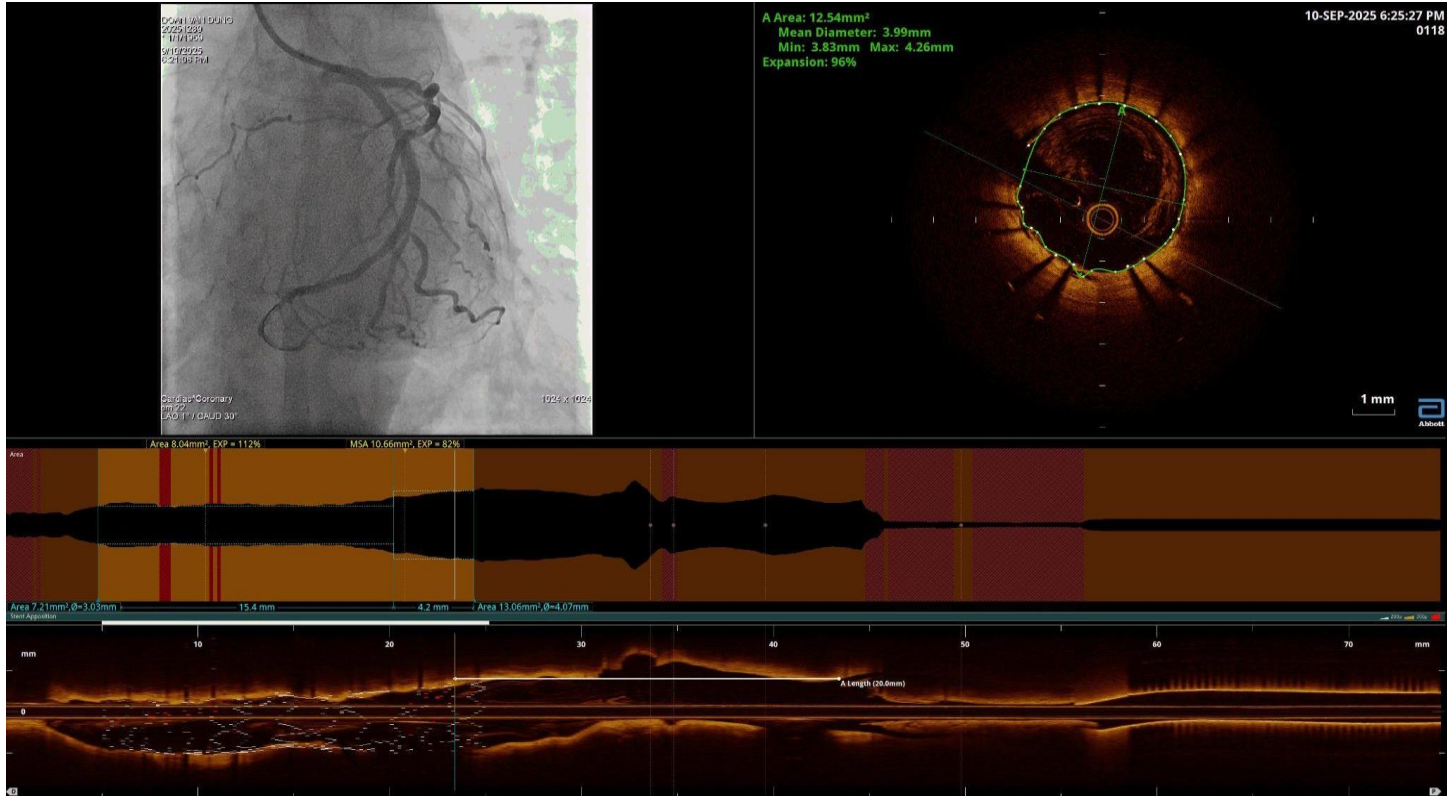
OCT LCx Post-PCI



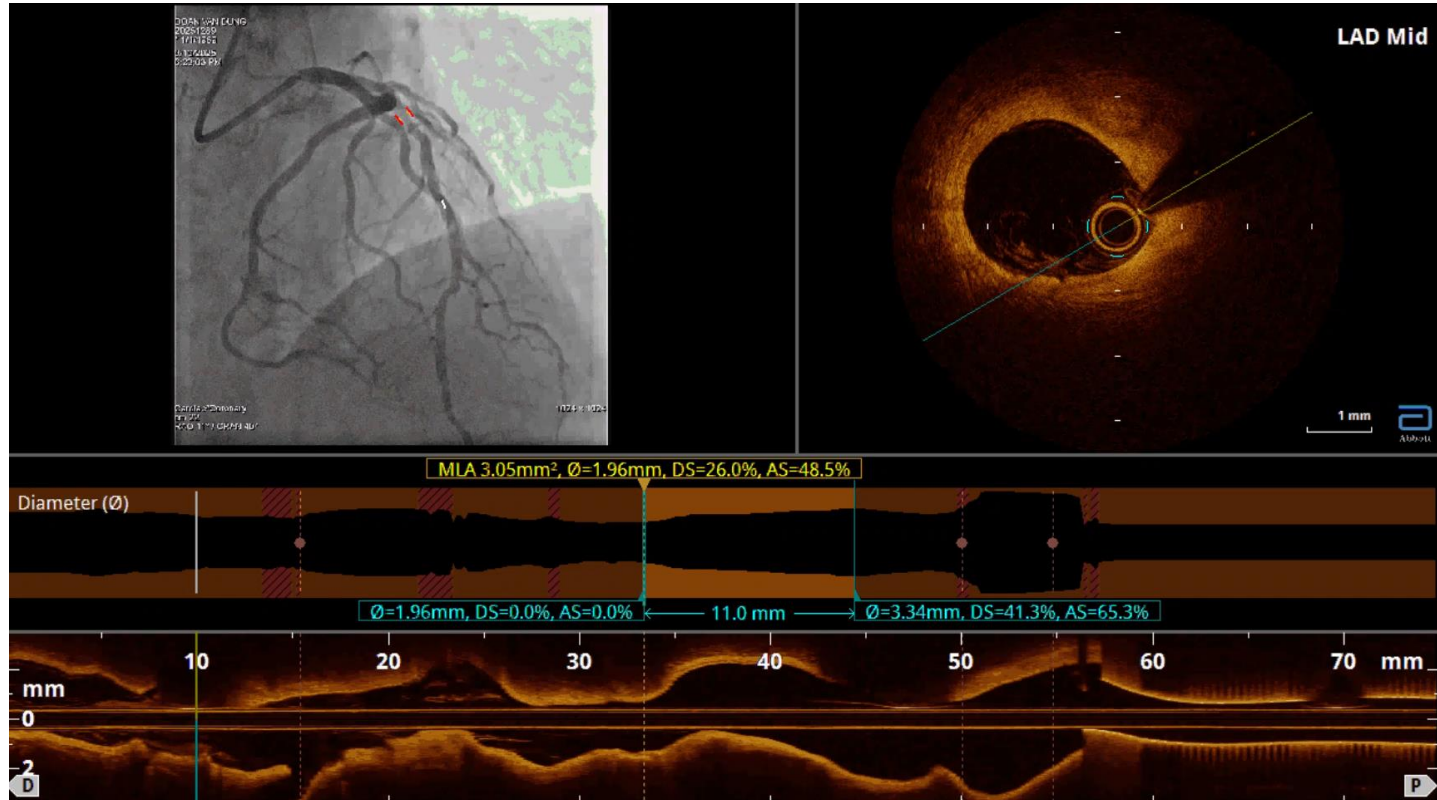
Apposition



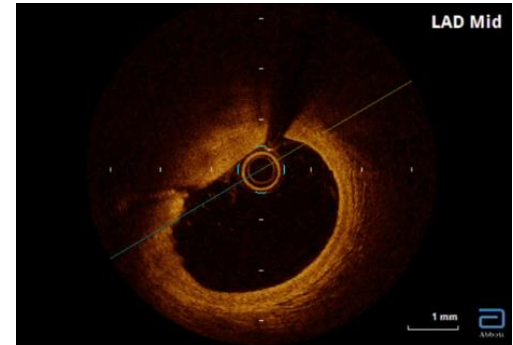
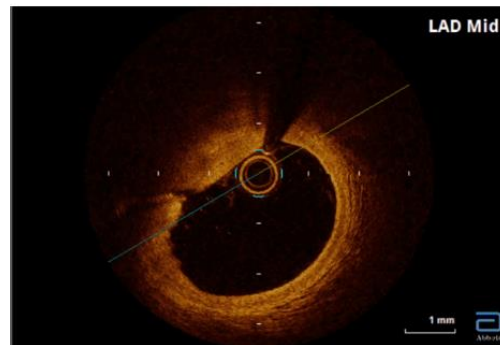
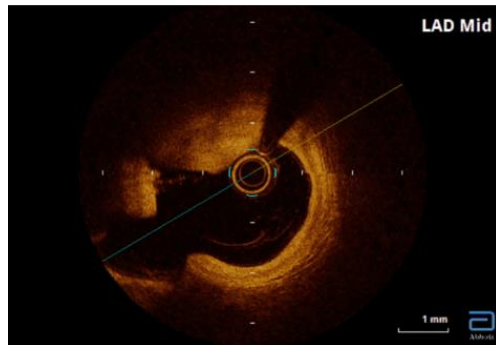
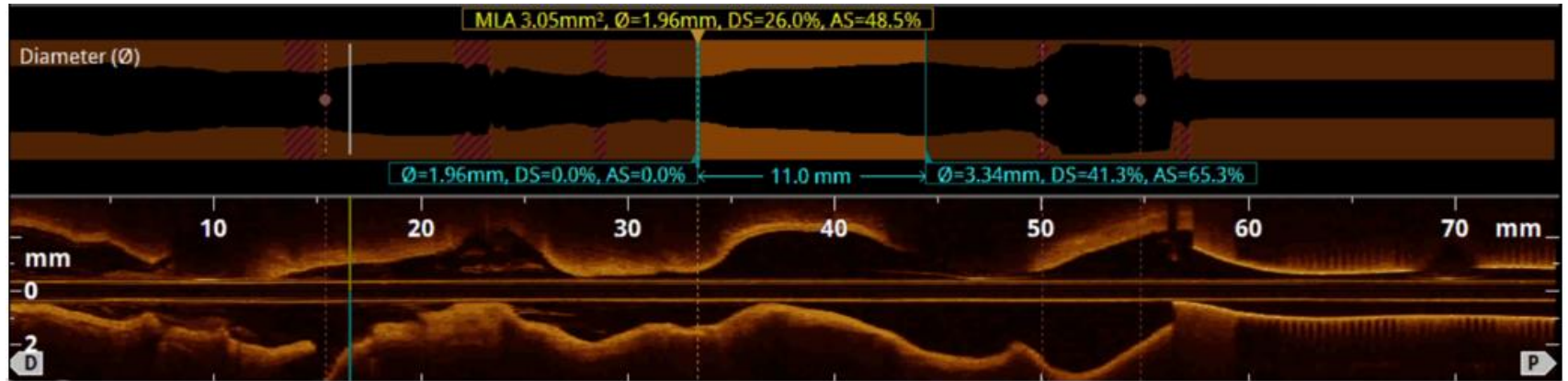
Xpansion



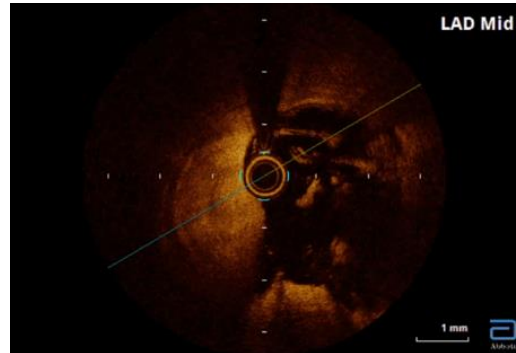
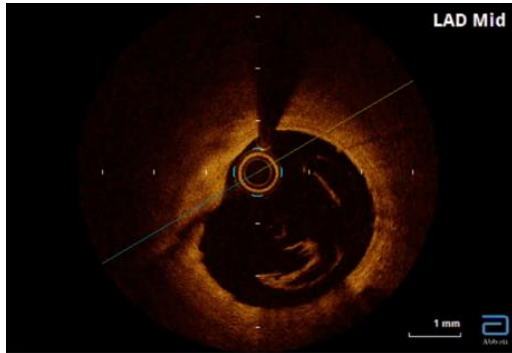
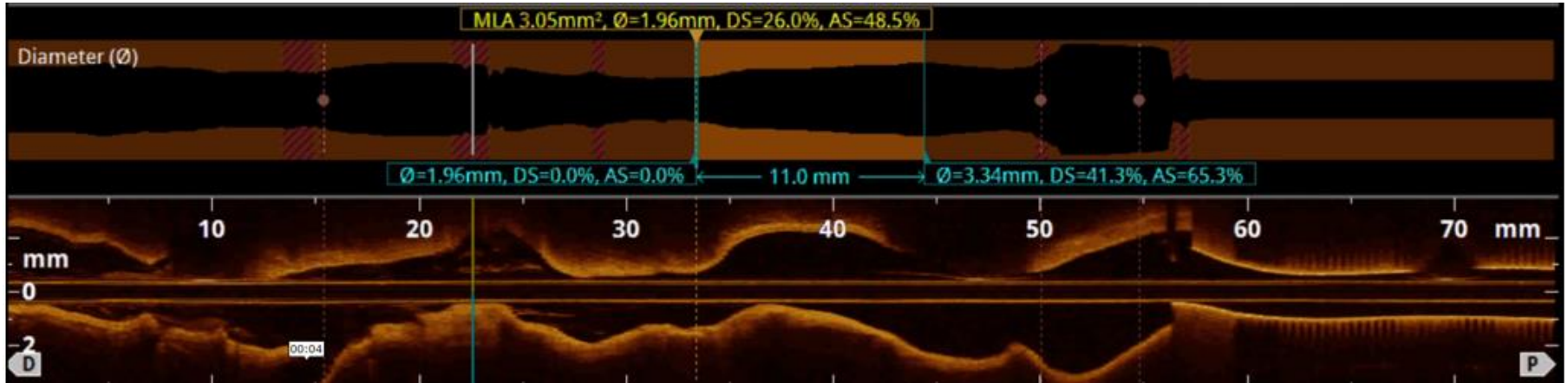
OCT LAD Pre-PCI



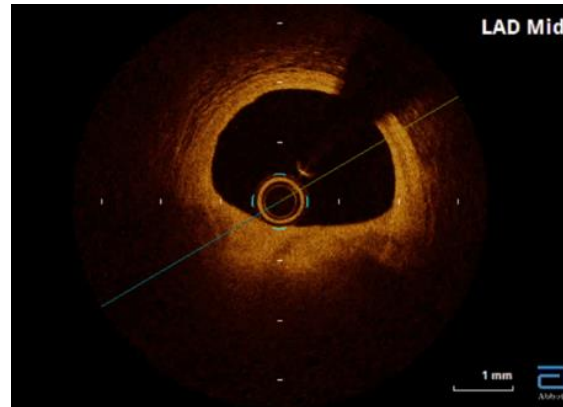
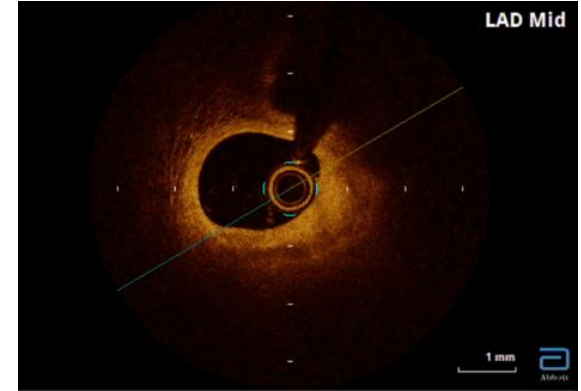
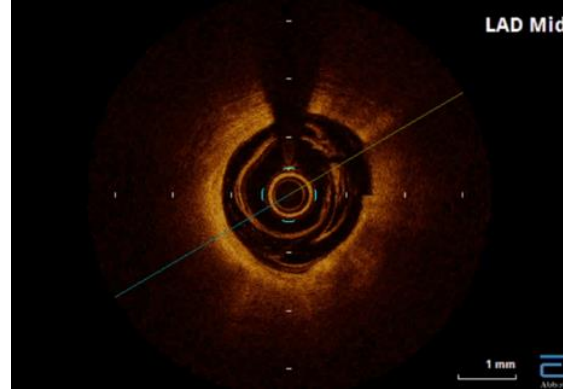
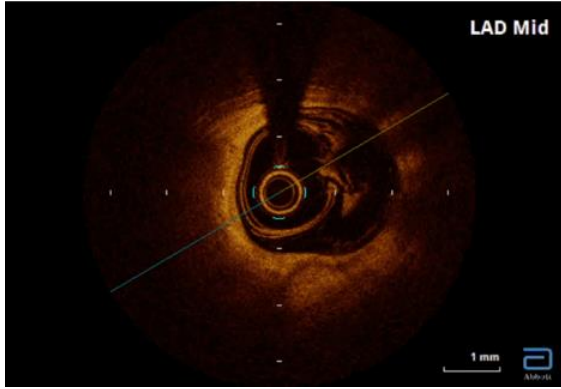
Morphology



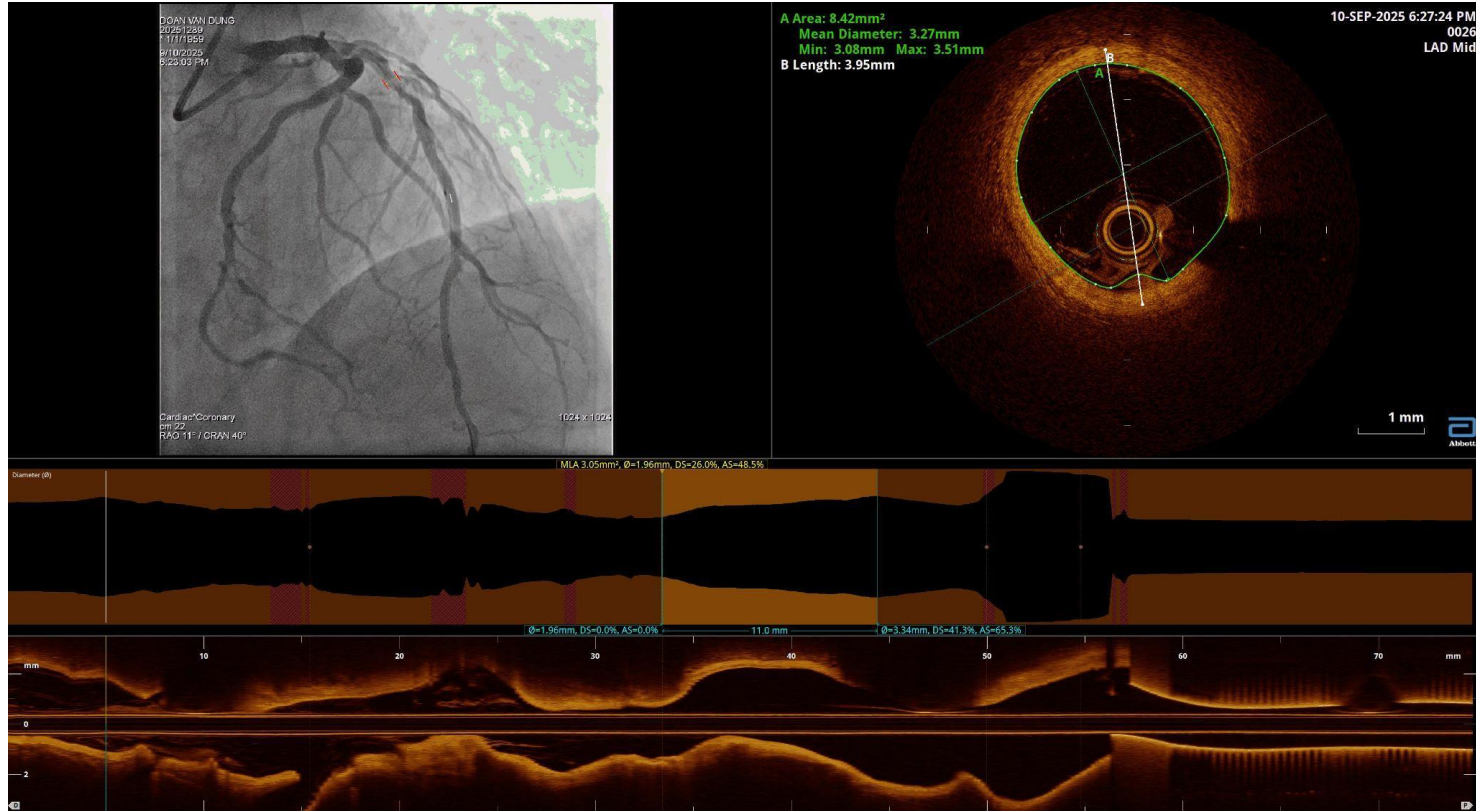
Morphology



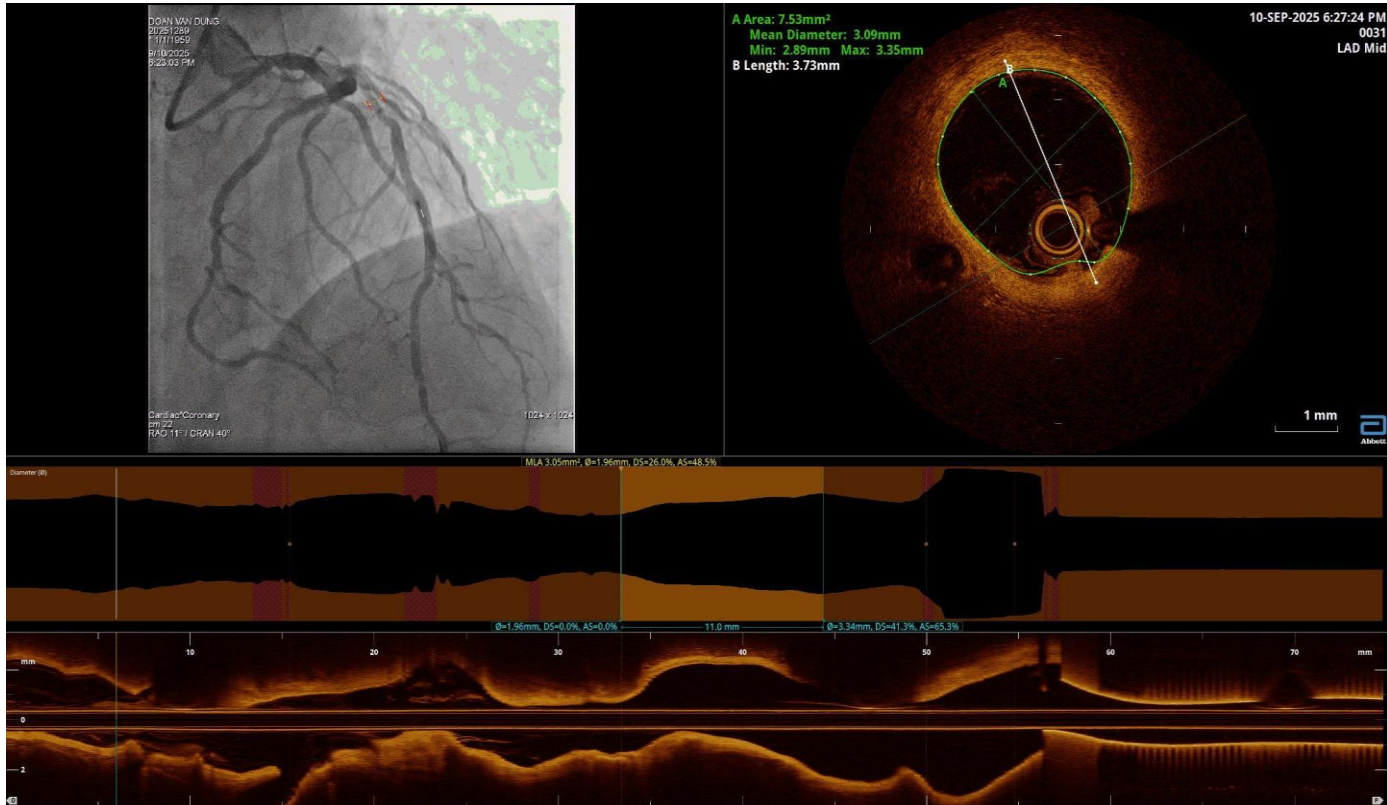
Morphology



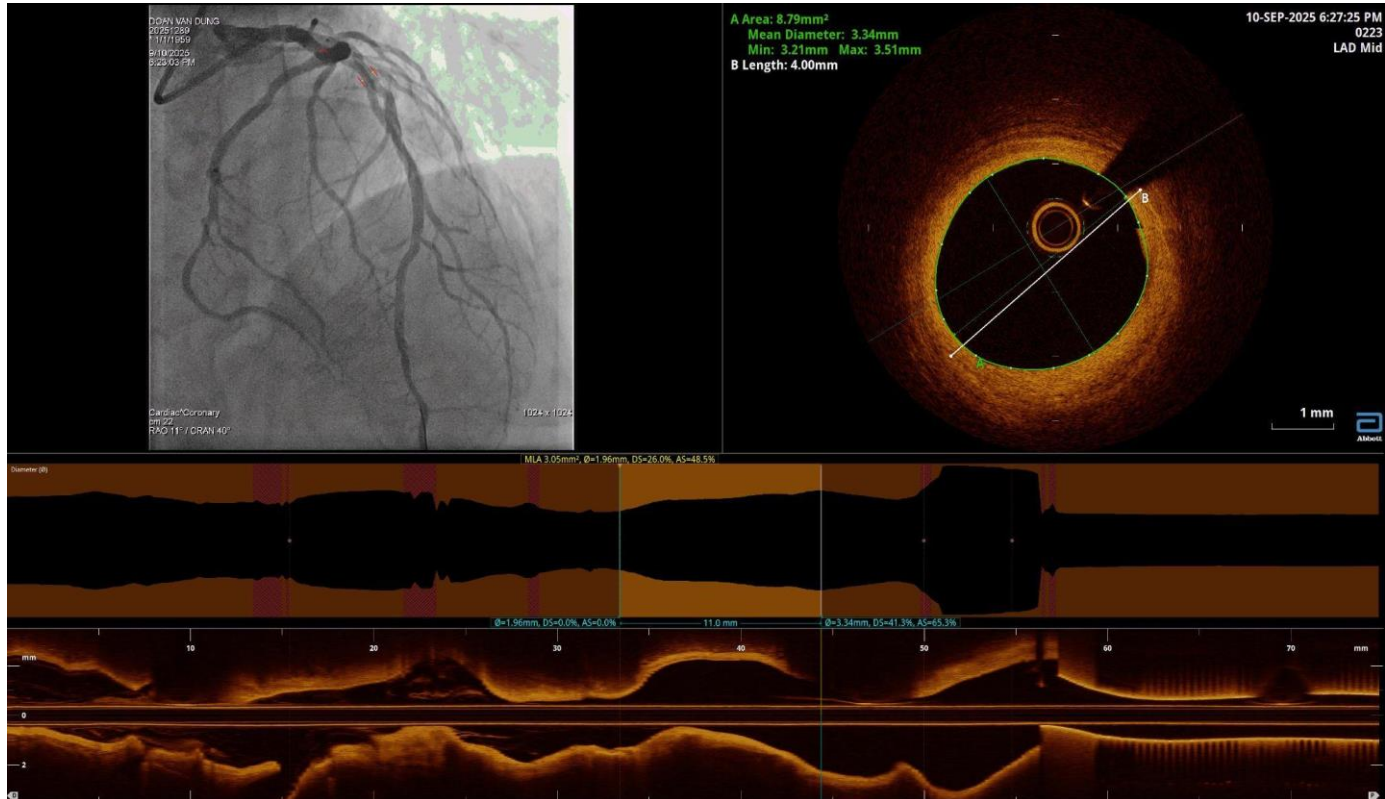
Diameter



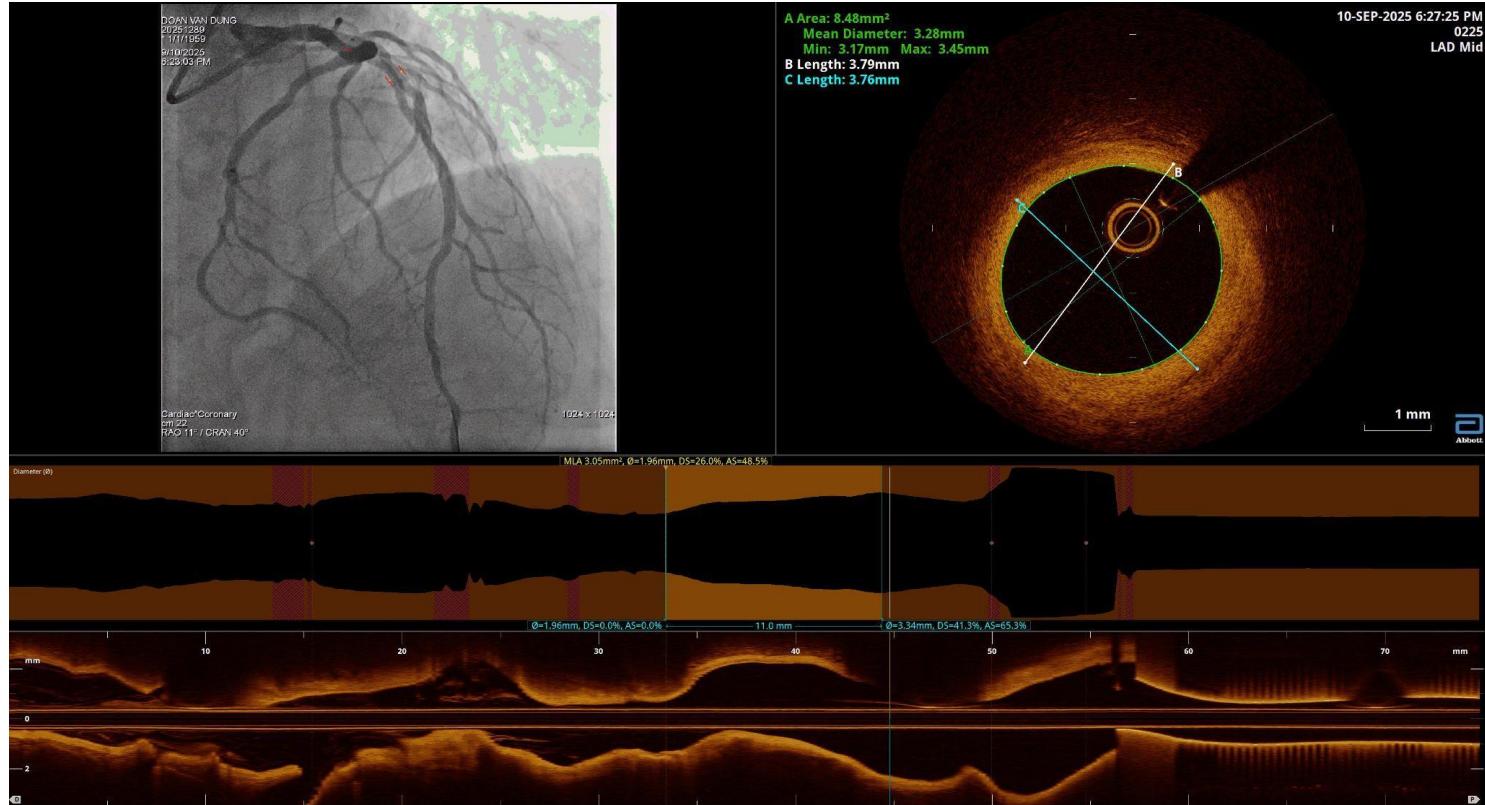
Diameter



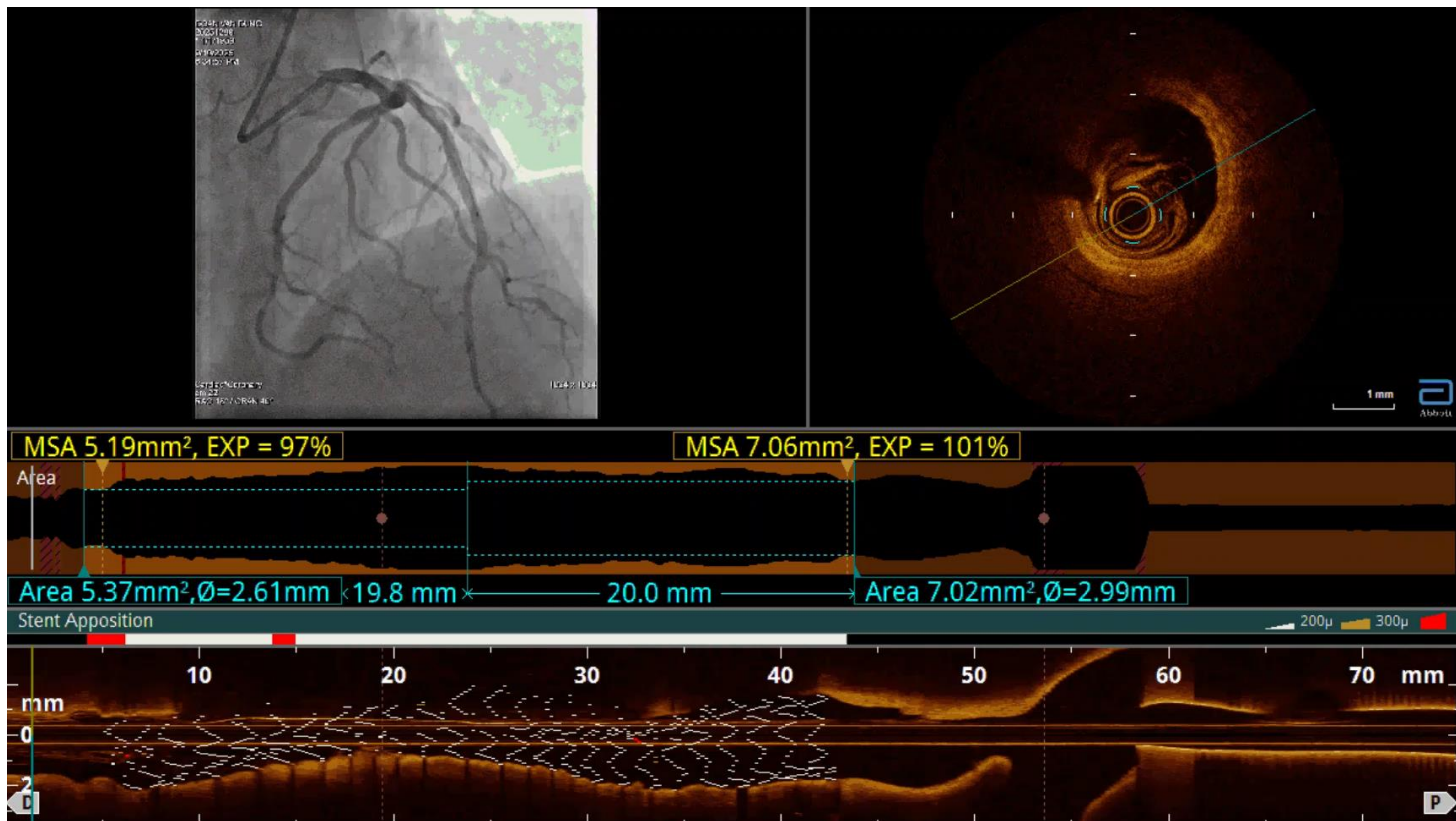
Diameter



Diameter



OCT LAD Post-PCI



OCT LAD Post-PCI

