



ASIC
CONGRESS 2026

ASIC COFFEE CORNER

ThS.BS. Trần Minh Trung

Tổng Thư ký Hội Tim mạch và Tim mạch Can Thiệp

An Giang

Khoa Nội Tim Mạch – BVĐK Kiên Giang



Case 1

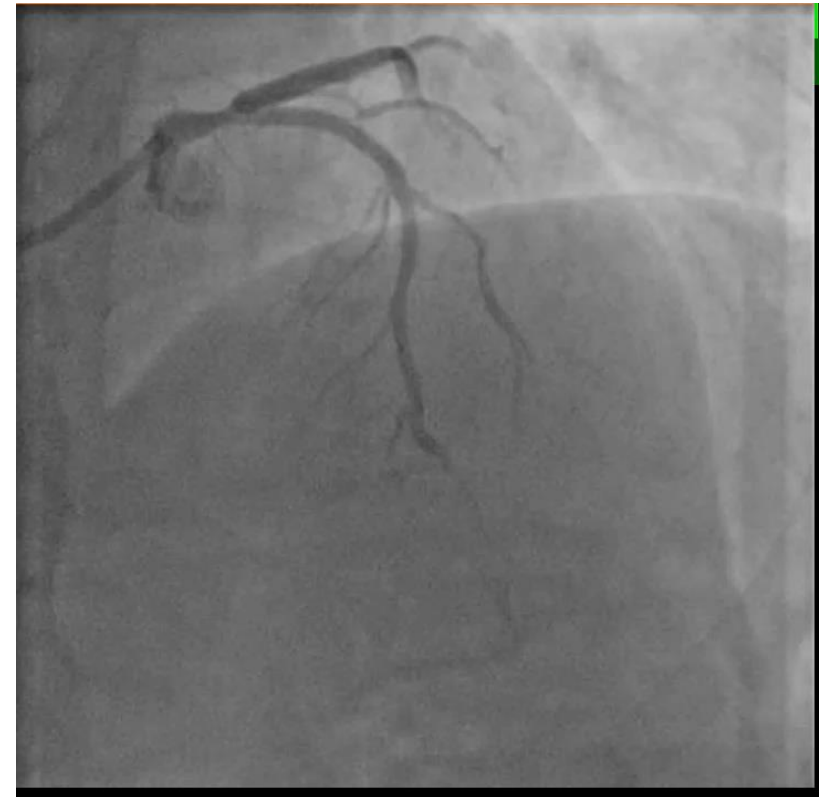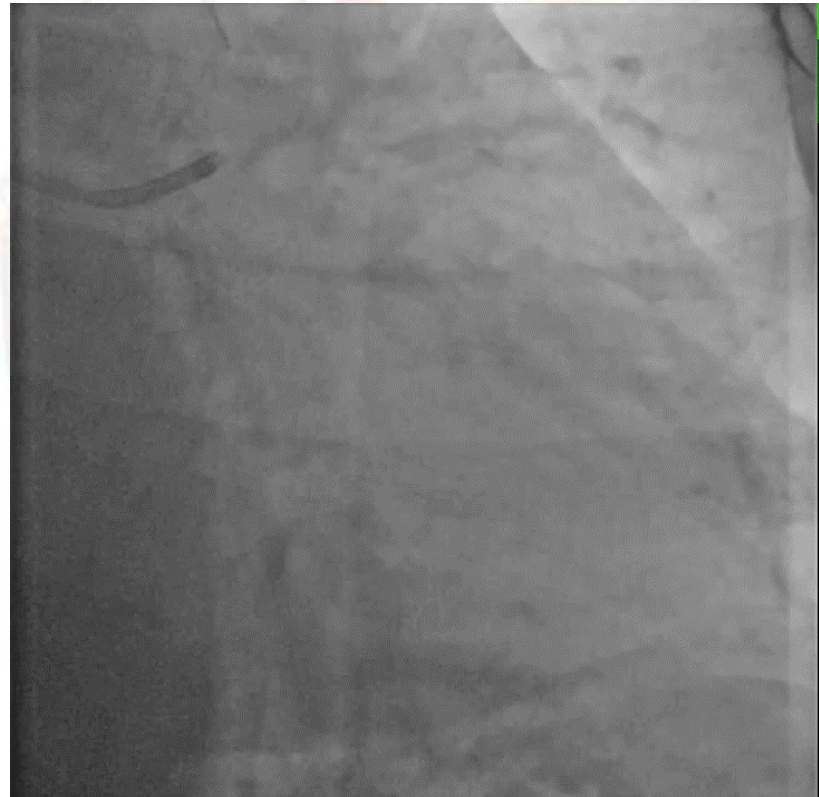
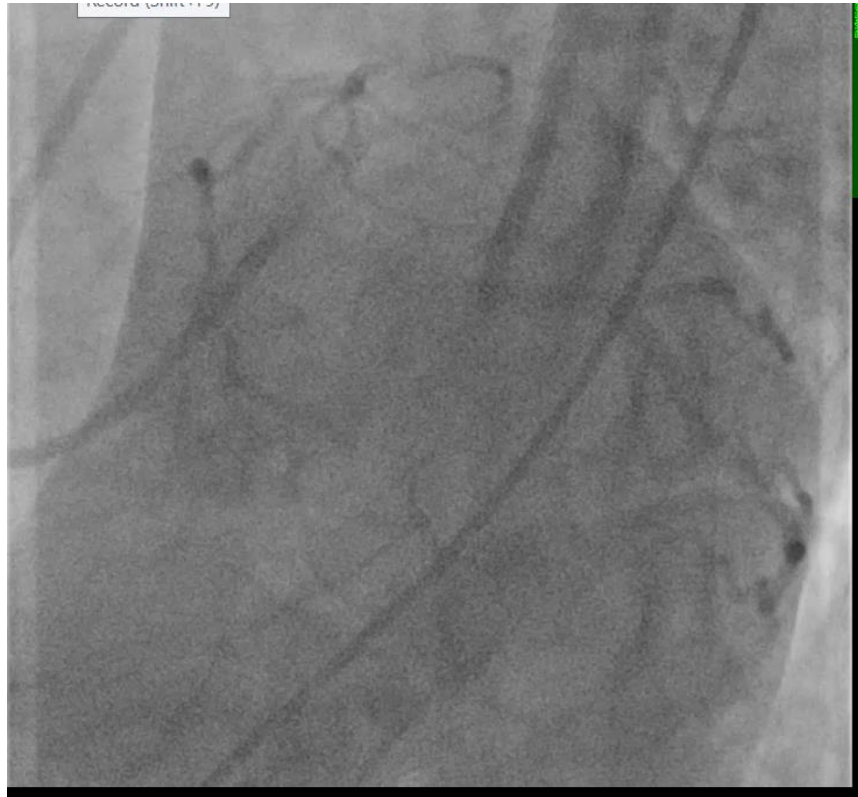LAM T T

Lâm sàng

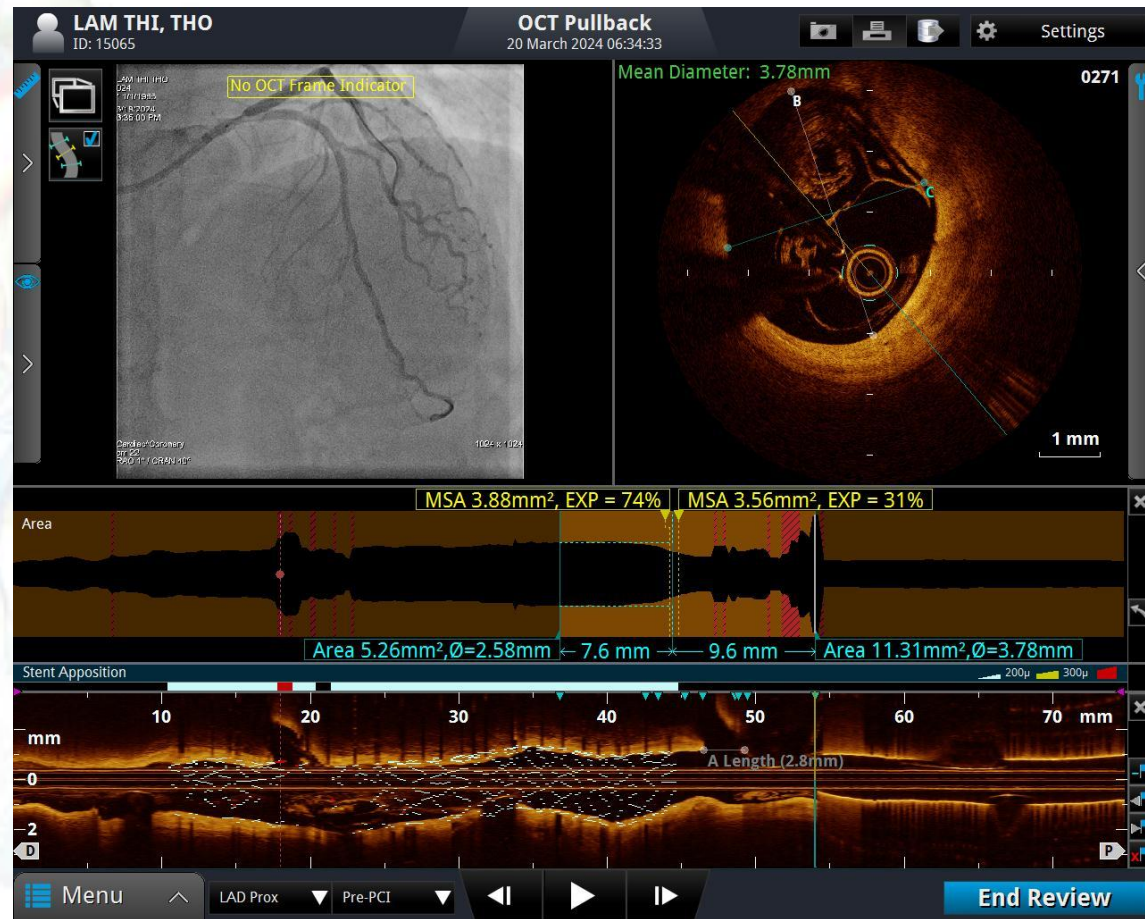
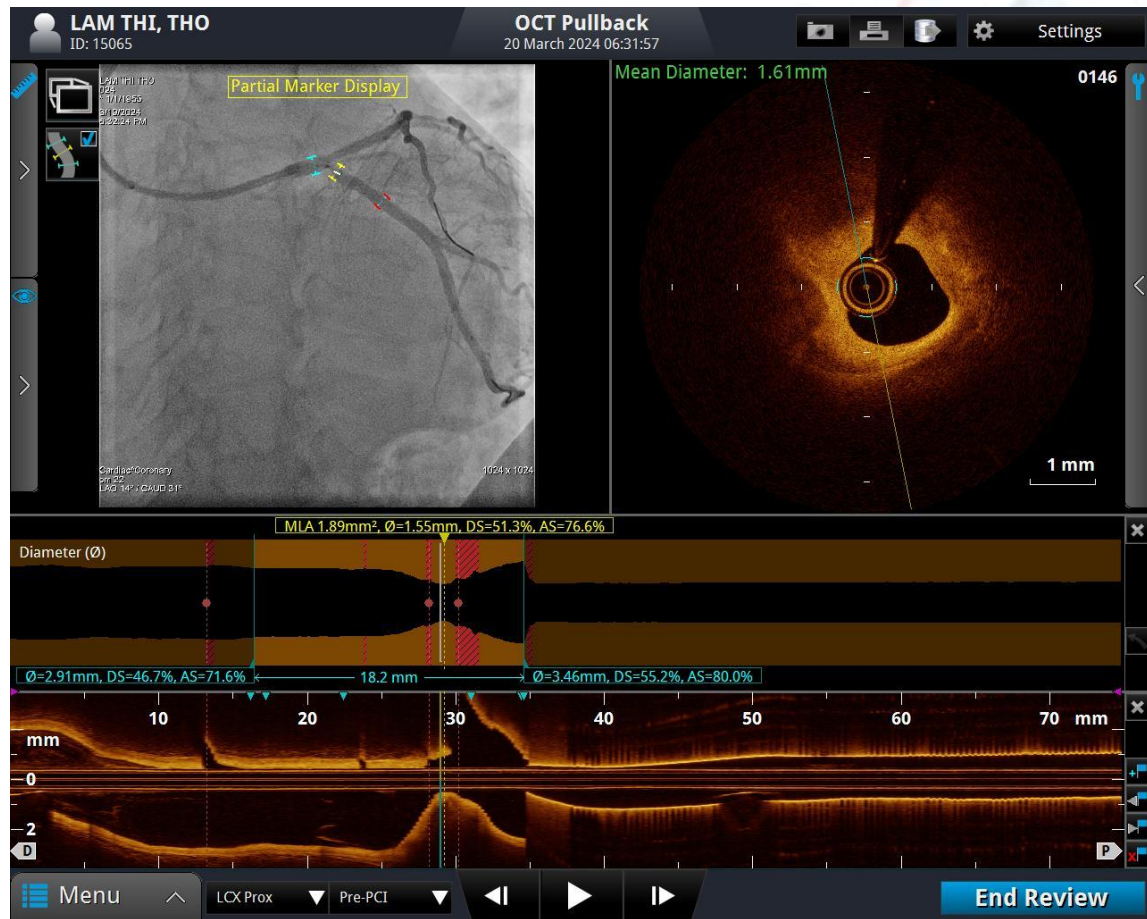


- Bệnh nhân: nữ, 69 tuổi
- Nhập viện vì đau thắt ngực
- Chẩn đoán: **CCS**
- Tiền căn: THA, ĐTĐ, BMV đã stent LADI-II (Combo Plus 2.53*33-3/2022)

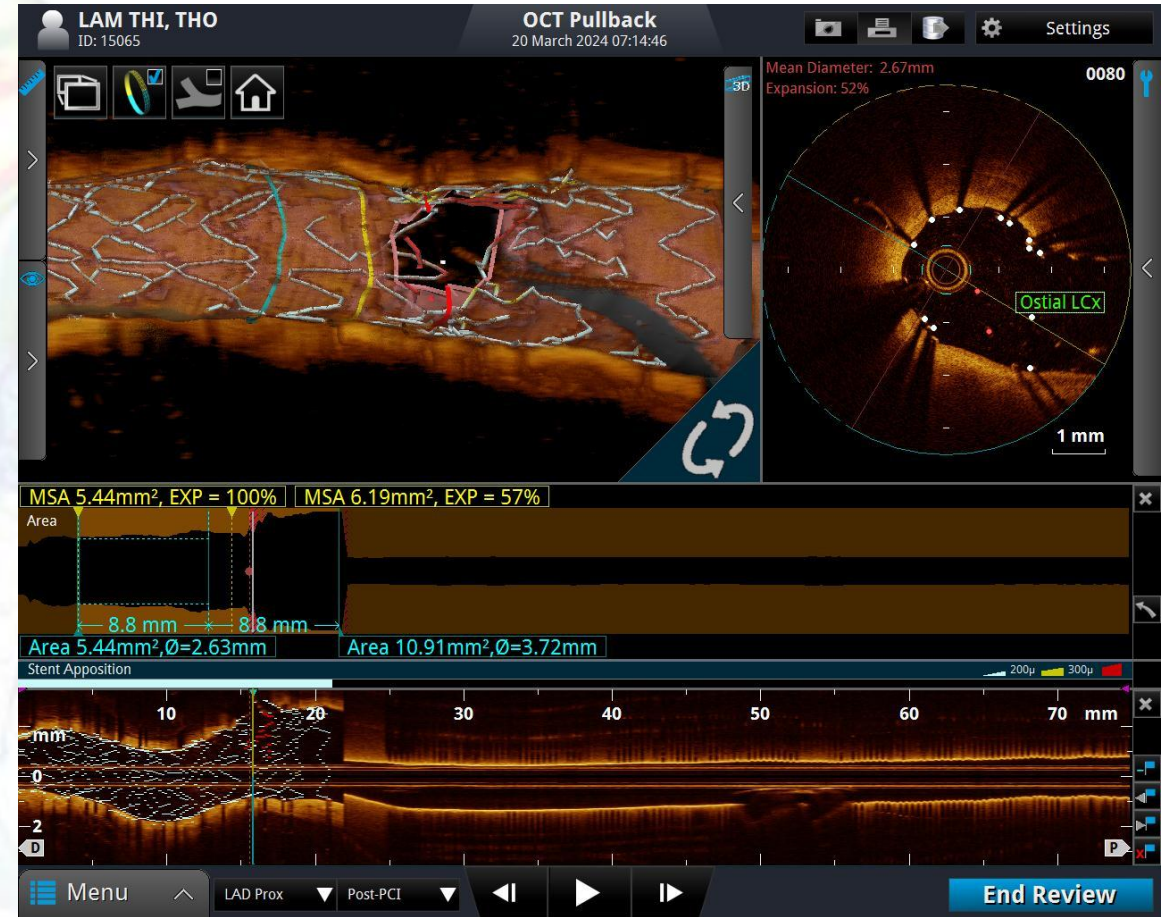
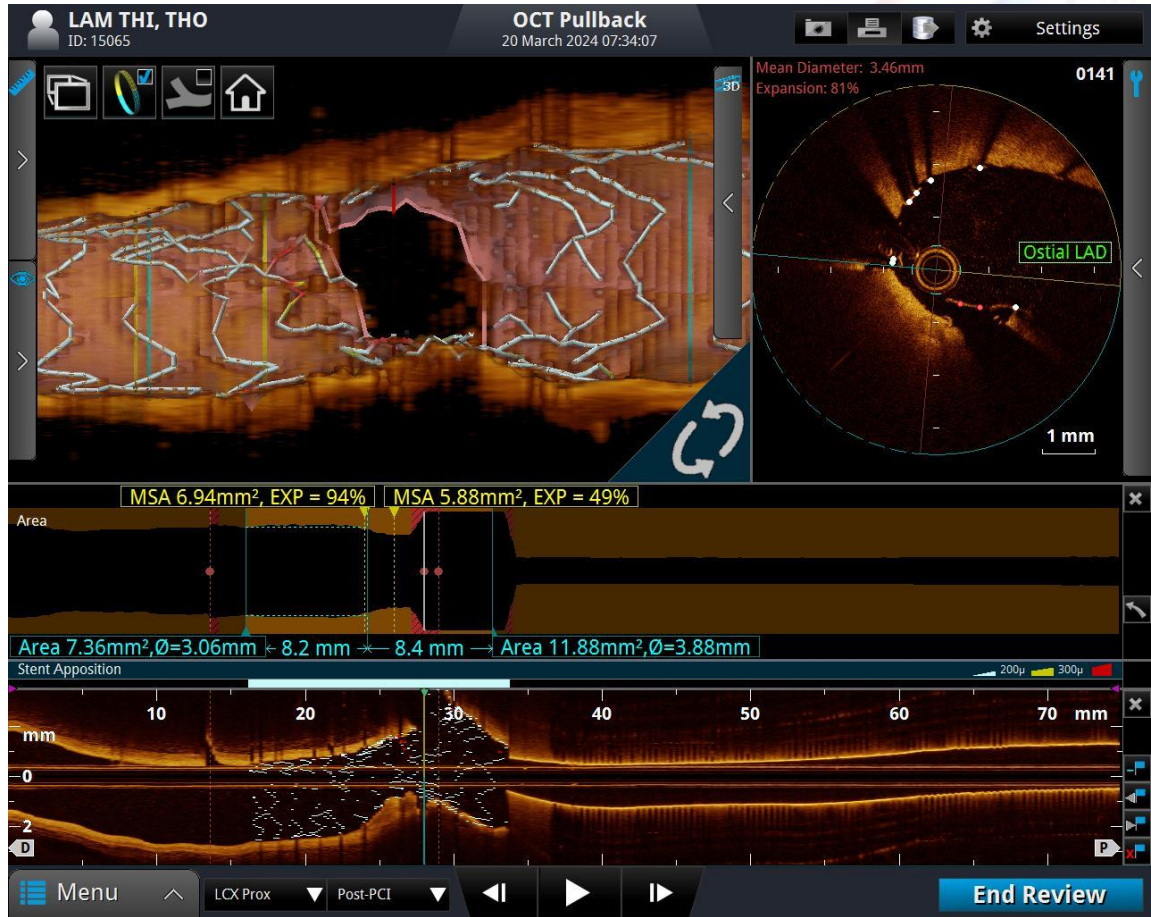
Angiogram



MLD



MAX





Case 2

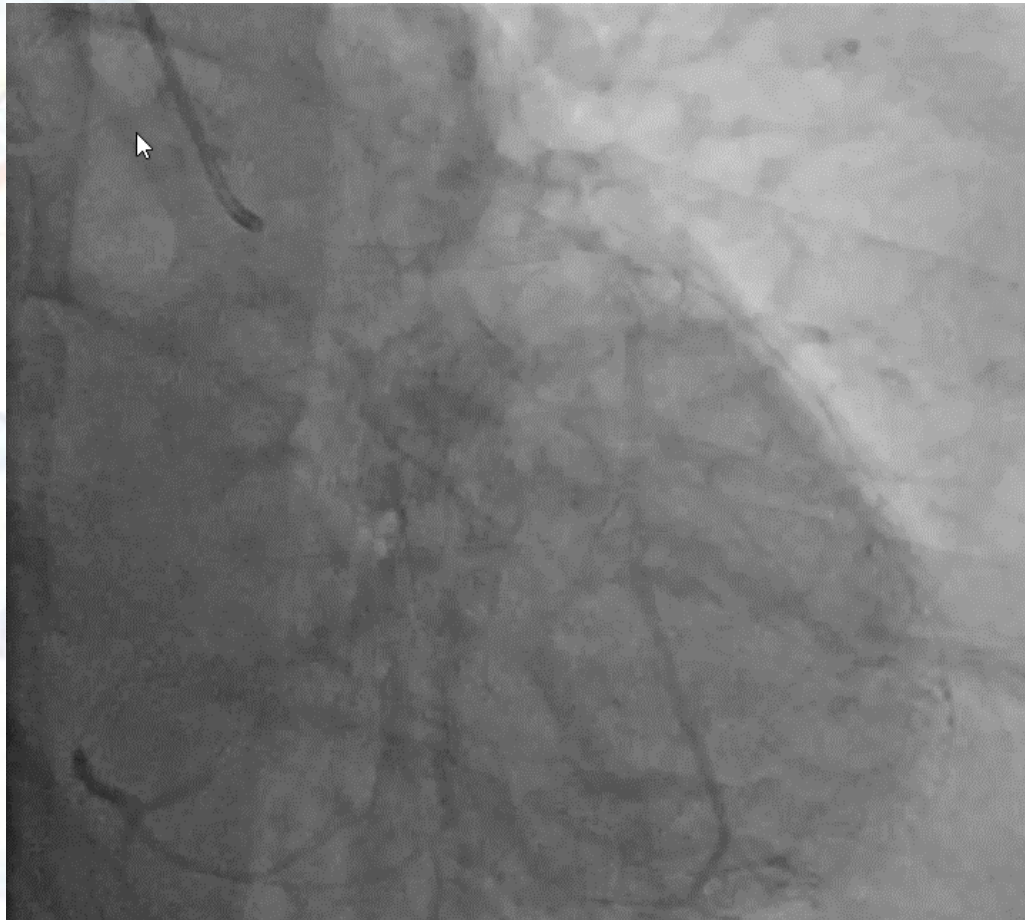
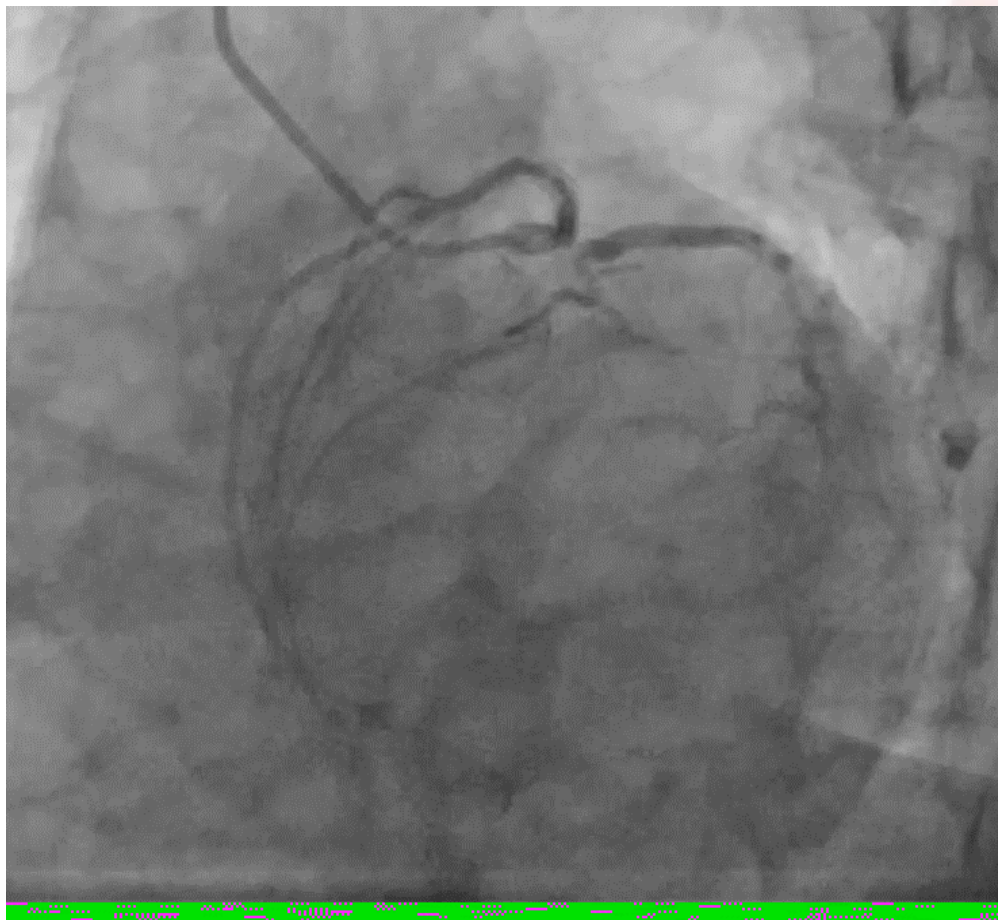NGO V L

Lâm sàng

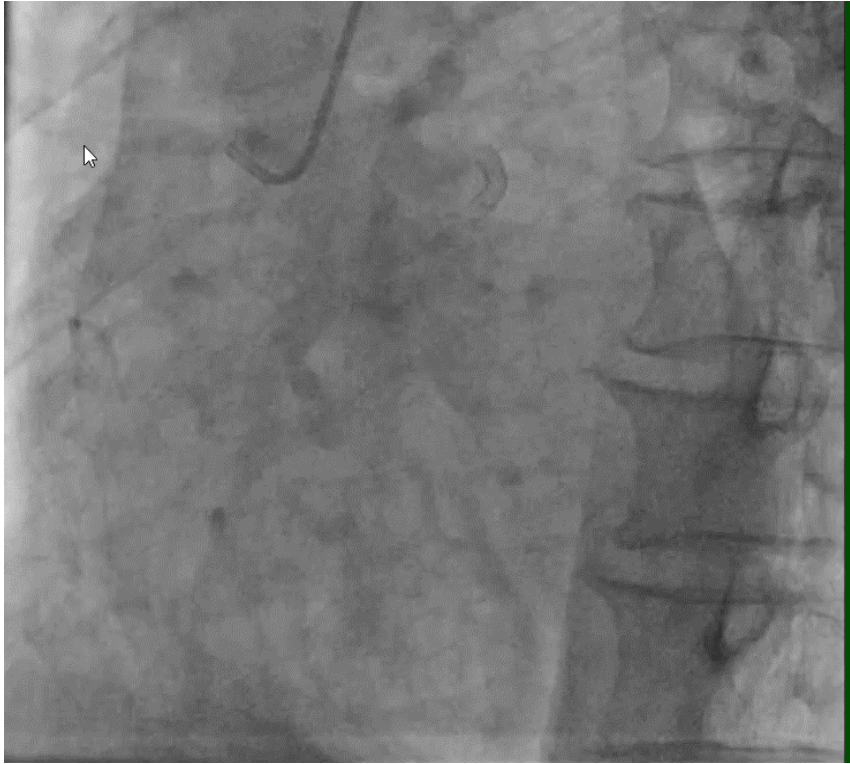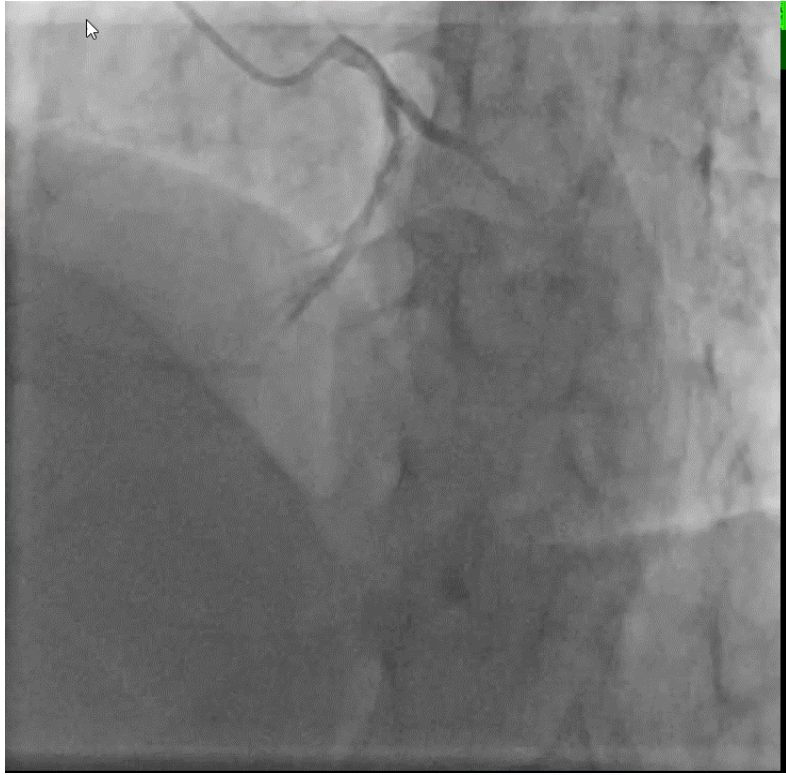
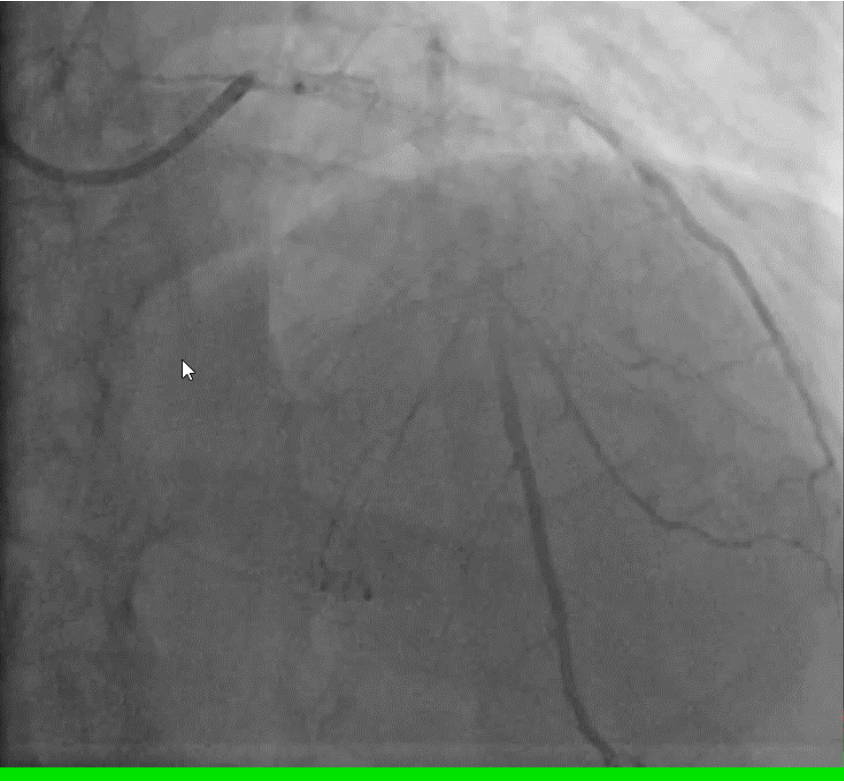An anatomical illustration of the human heart, showing the four chambers (right and left atria and ventricles) and the major blood vessels (superior and inferior vena cava, aorta, and pulmonary artery and vein). The heart is rendered in a semi-transparent, light blue and yellow color scheme, positioned centrally in the background of the slide.

- Bệnh nhân nam, 61 tuổi
- Vào viện vì đau thắt ngực
- Chẩn đoán: **NSTEMI**
- Tiền sử: Hút thuốc lá, THA, ĐTĐ, CAD stent 10 năm

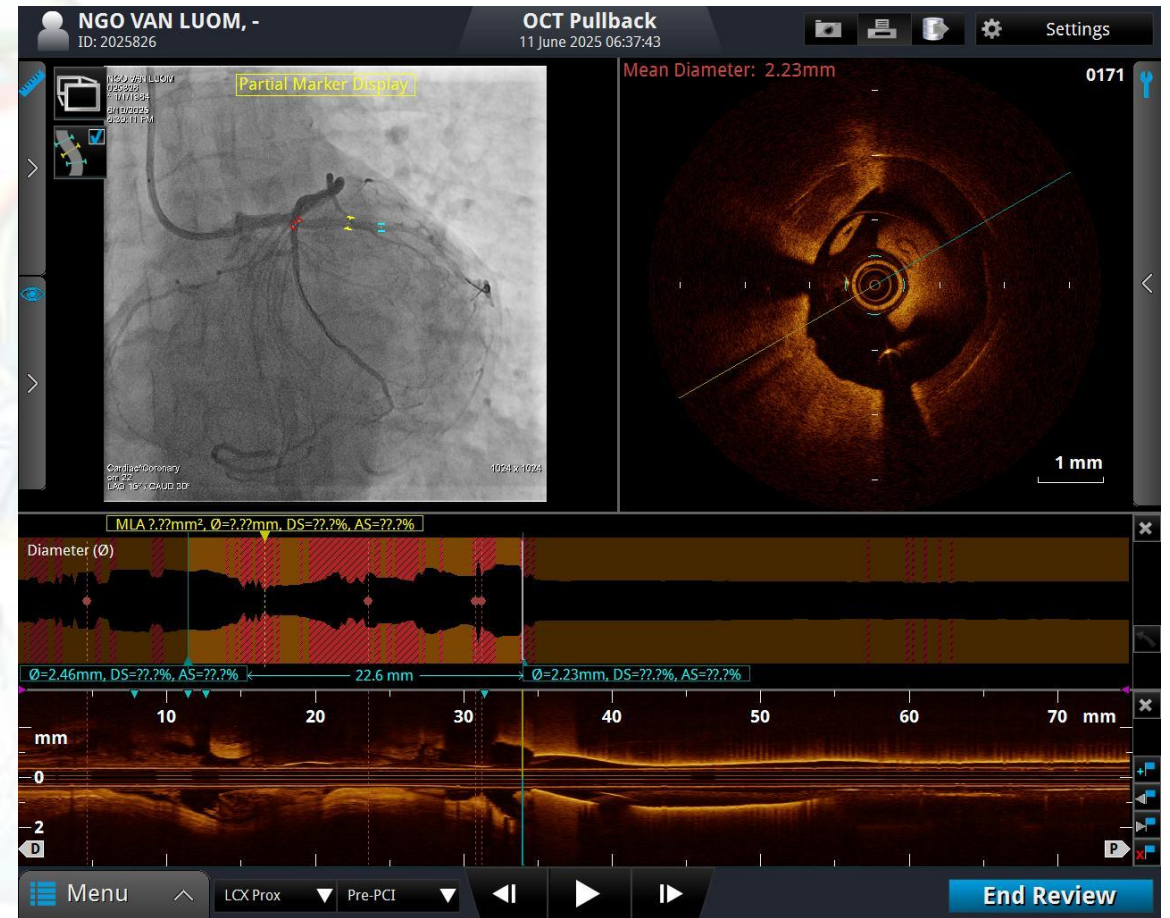
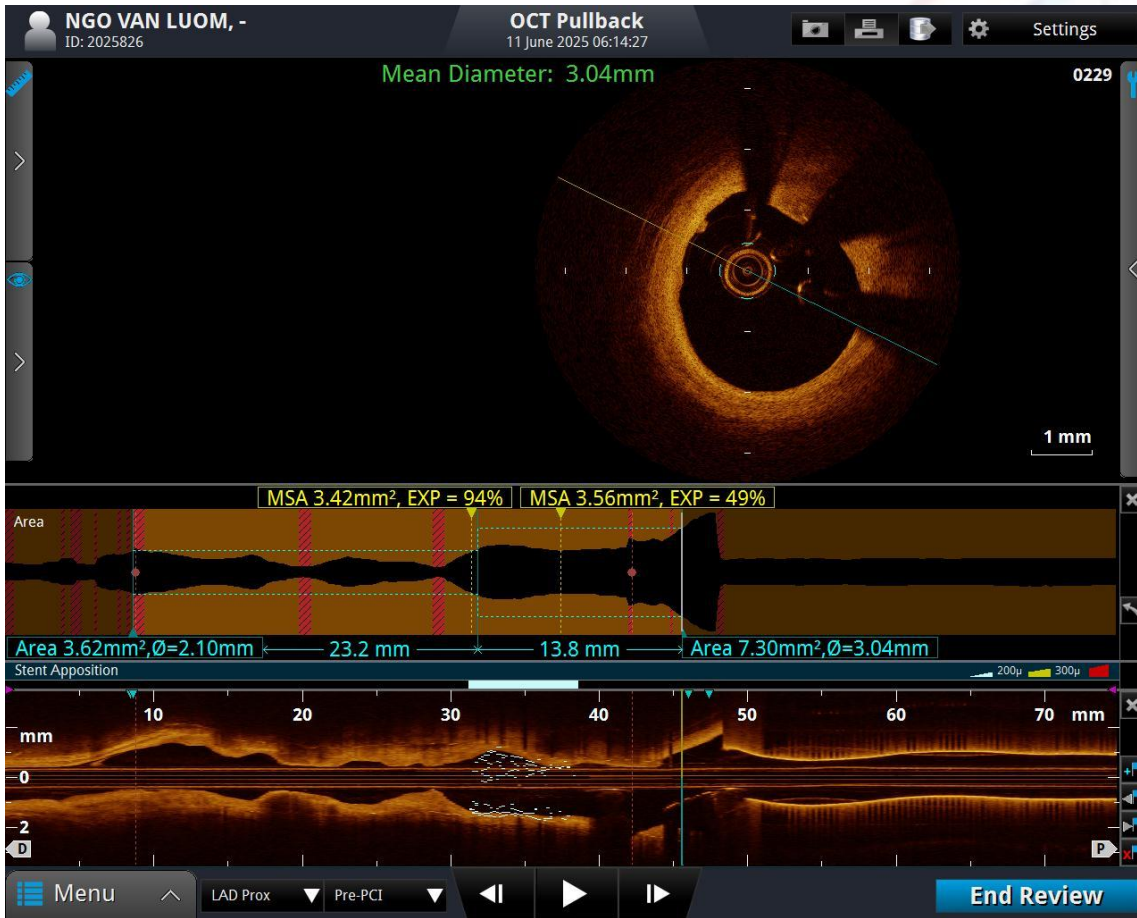
Angiogram



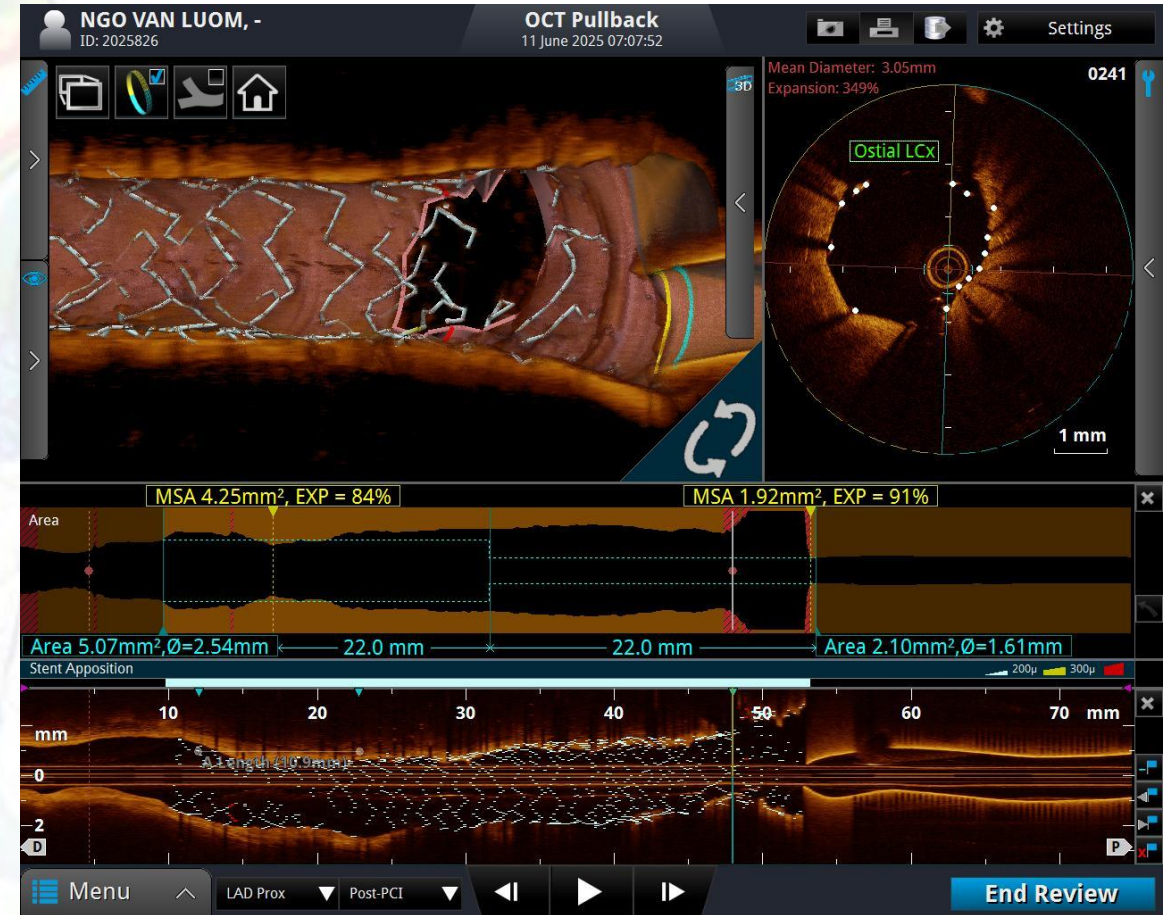
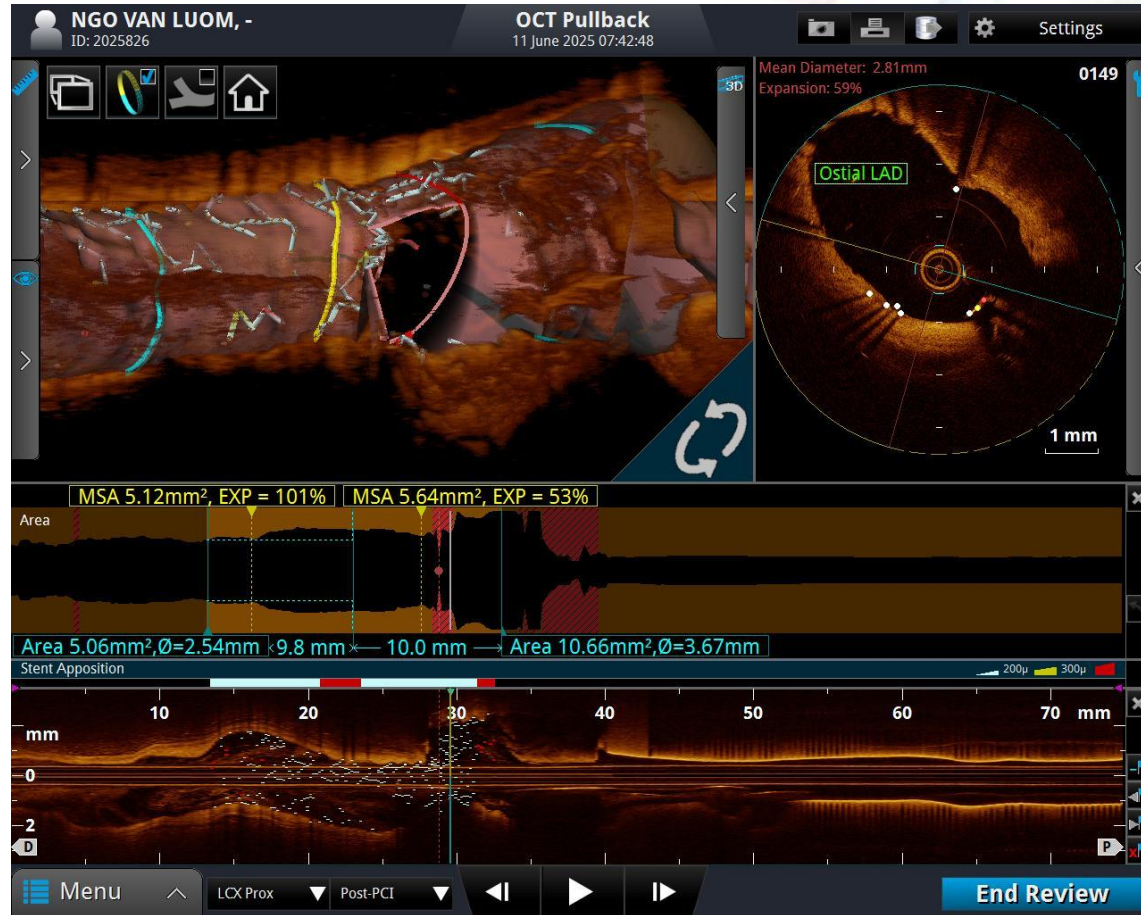Angiogram



MLD



MAX



Thank you for your attention !

