

# Case 1

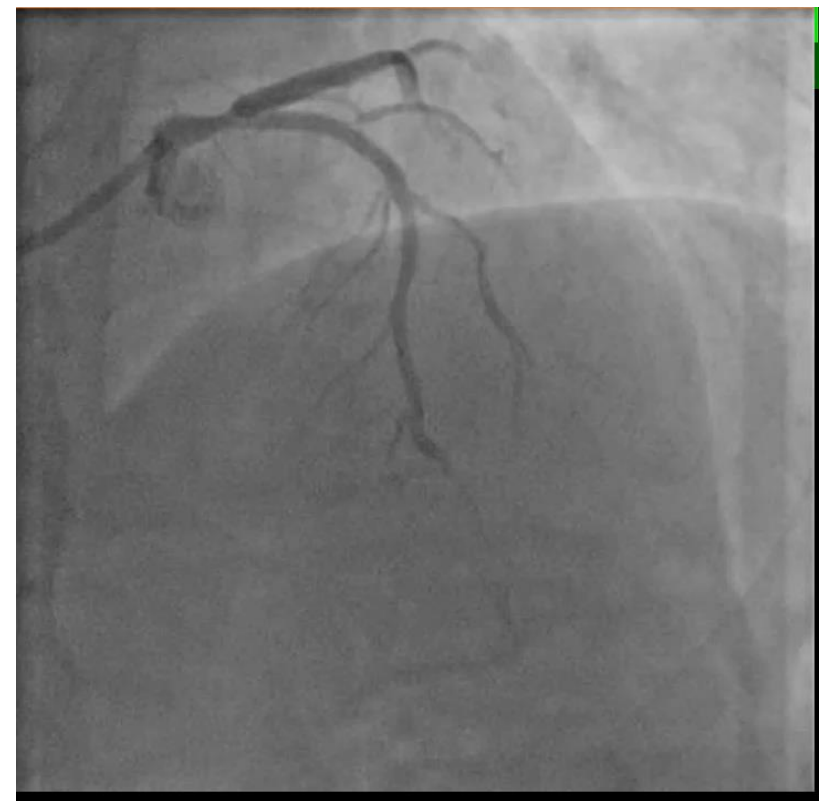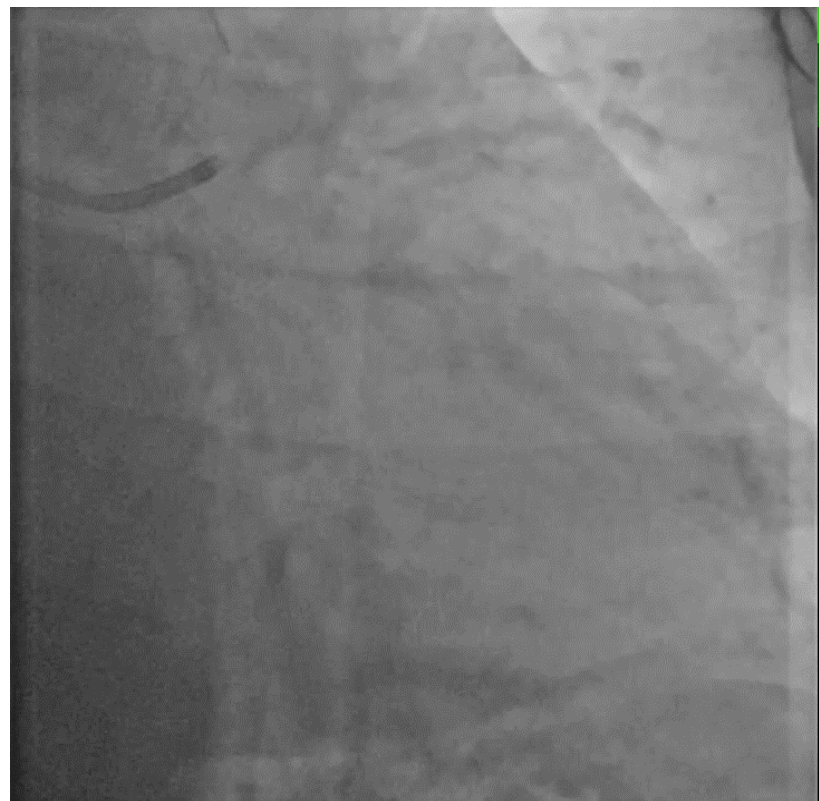
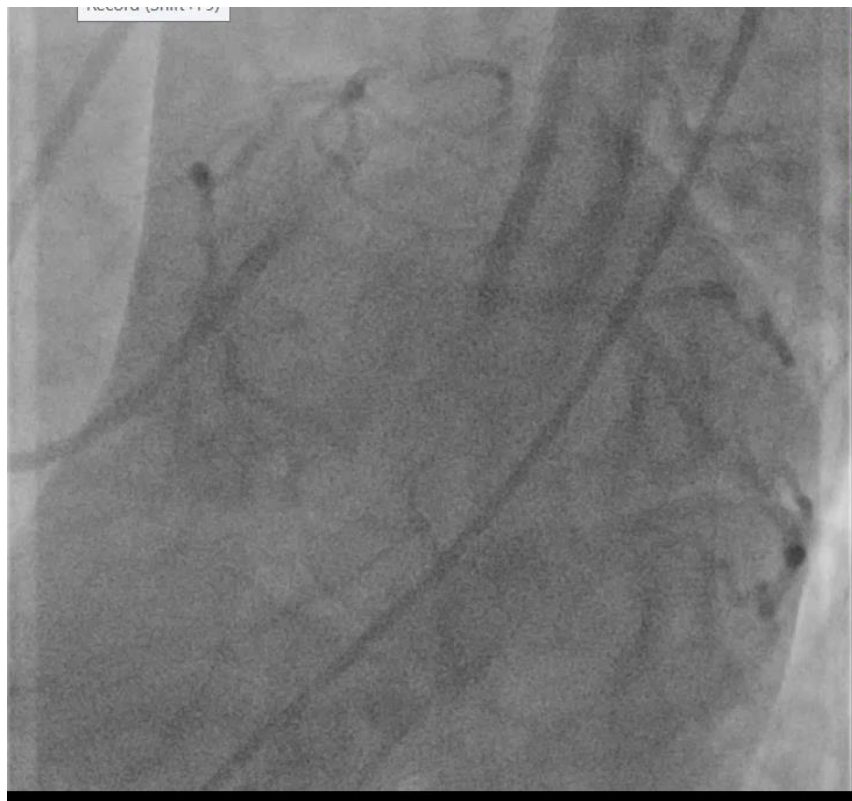## LAM THI T

ThS.BS. Trần Minh Trung

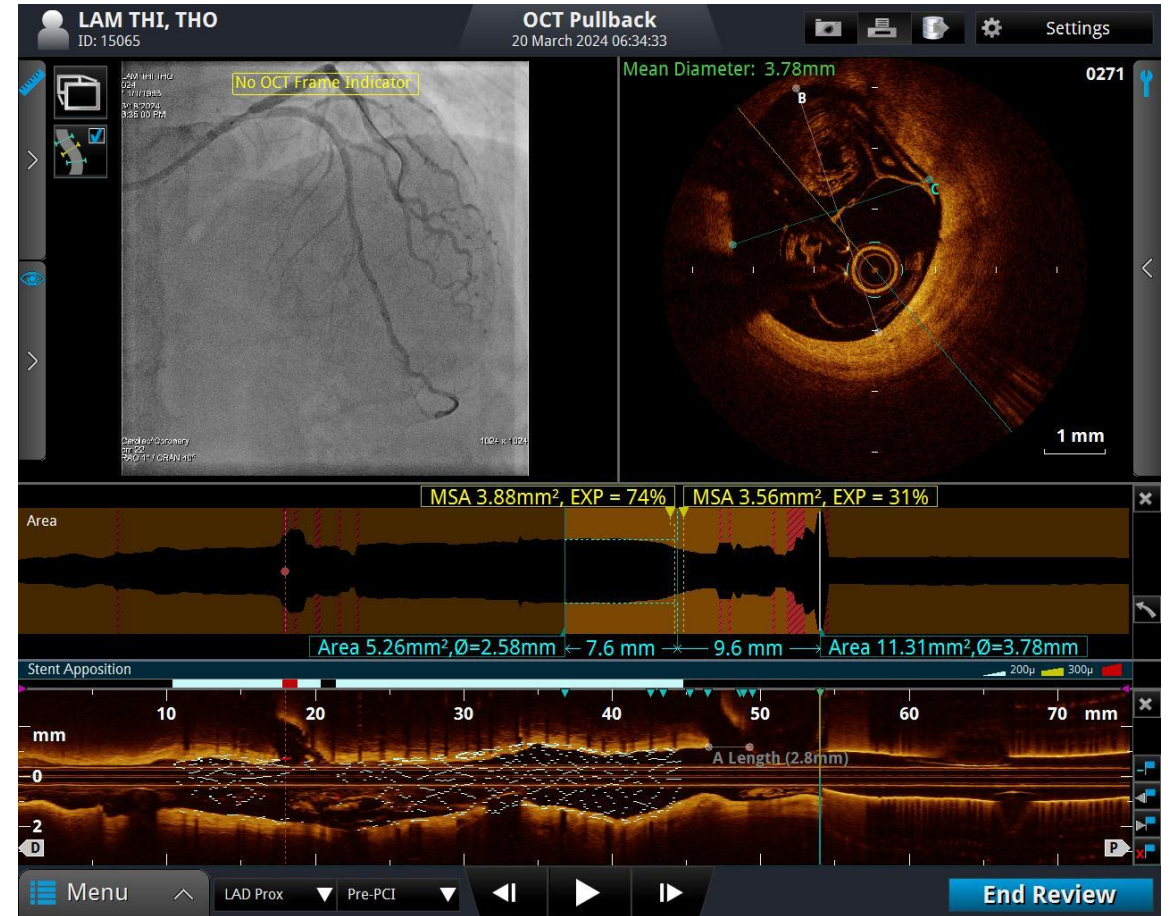
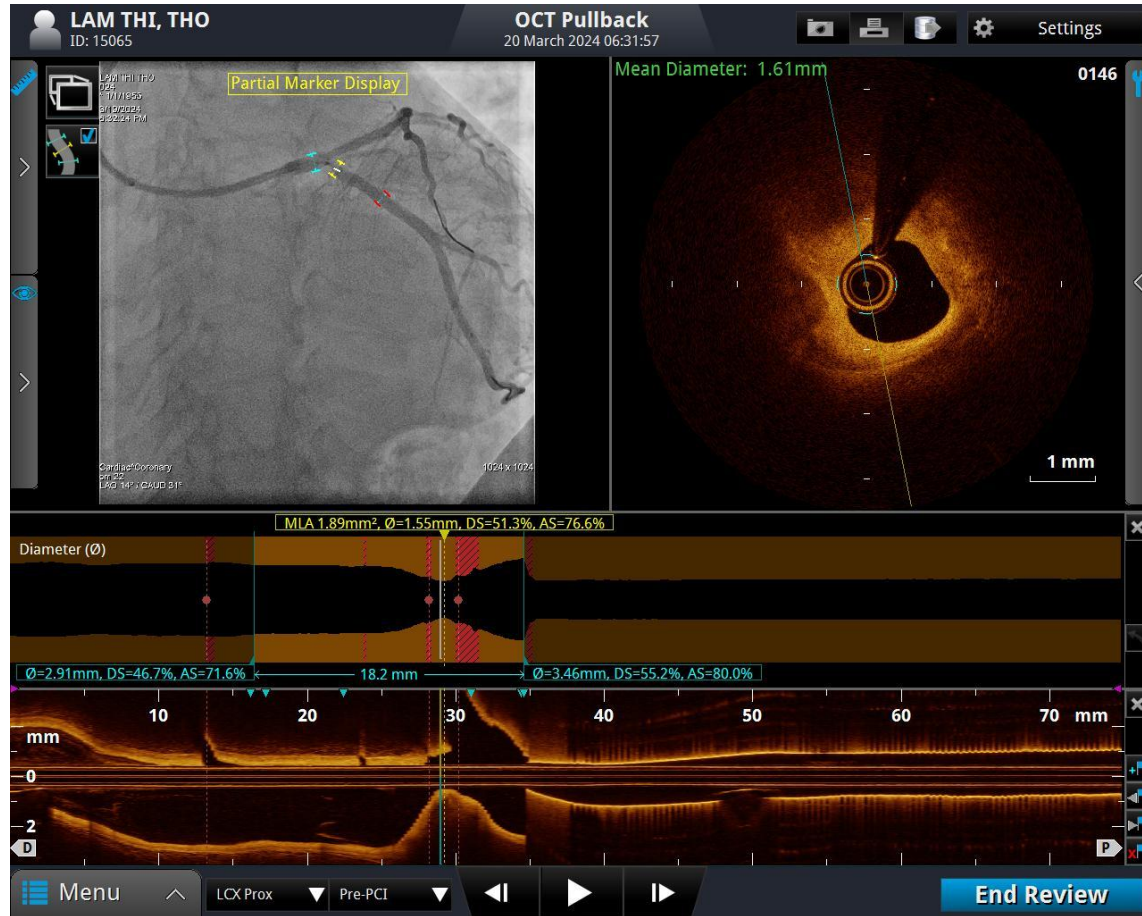
# Lâm sàng

- Bệnh nhân: nữ, 69 tuổi
- Nhập viện vì đau thắt ngực
- Chẩn đoán: **CCS**
- Tiền căn: THA, ĐTĐ, BMV đã stent LAD

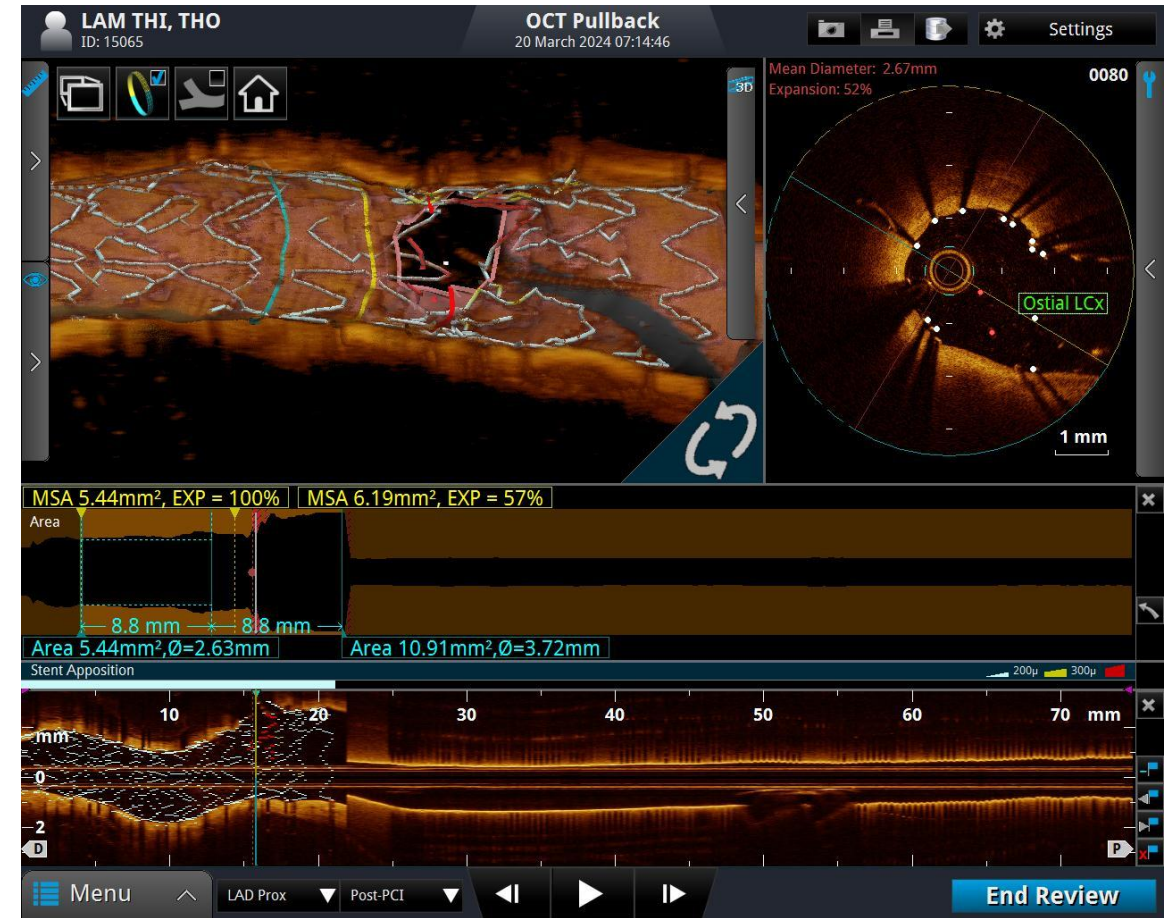
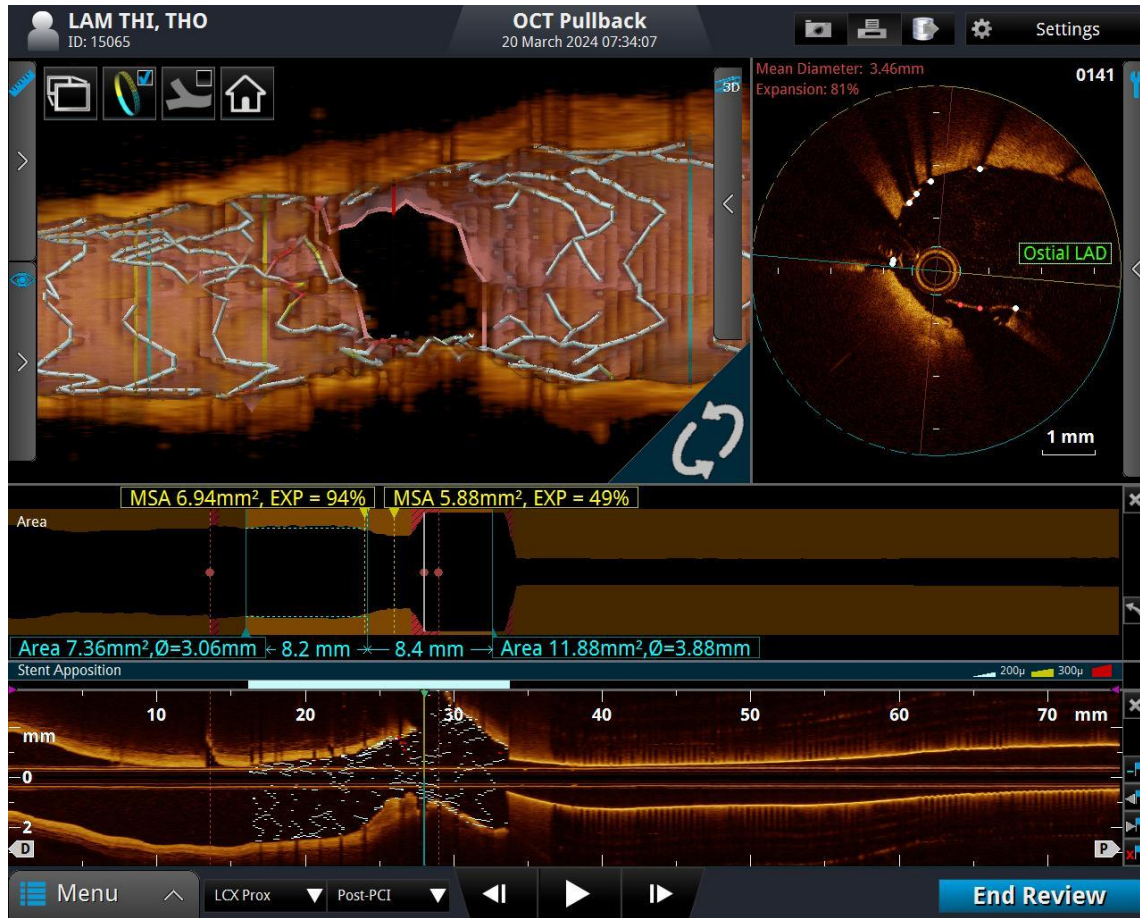
# Angiogram



# MLD



# MAX

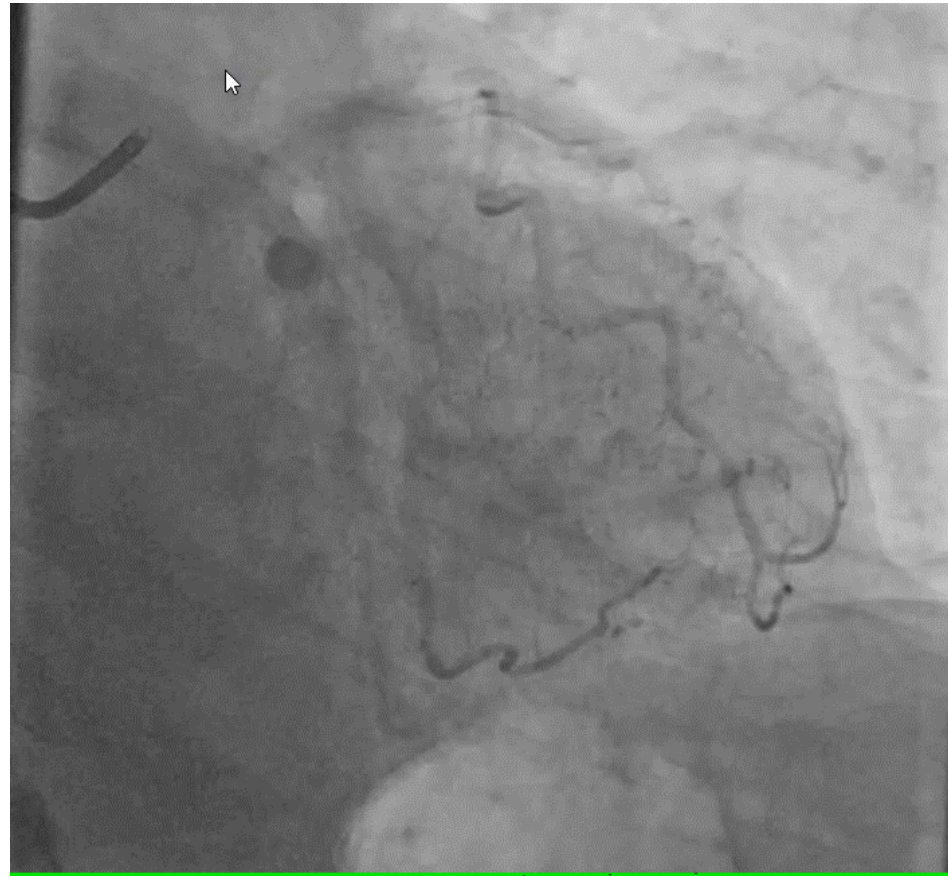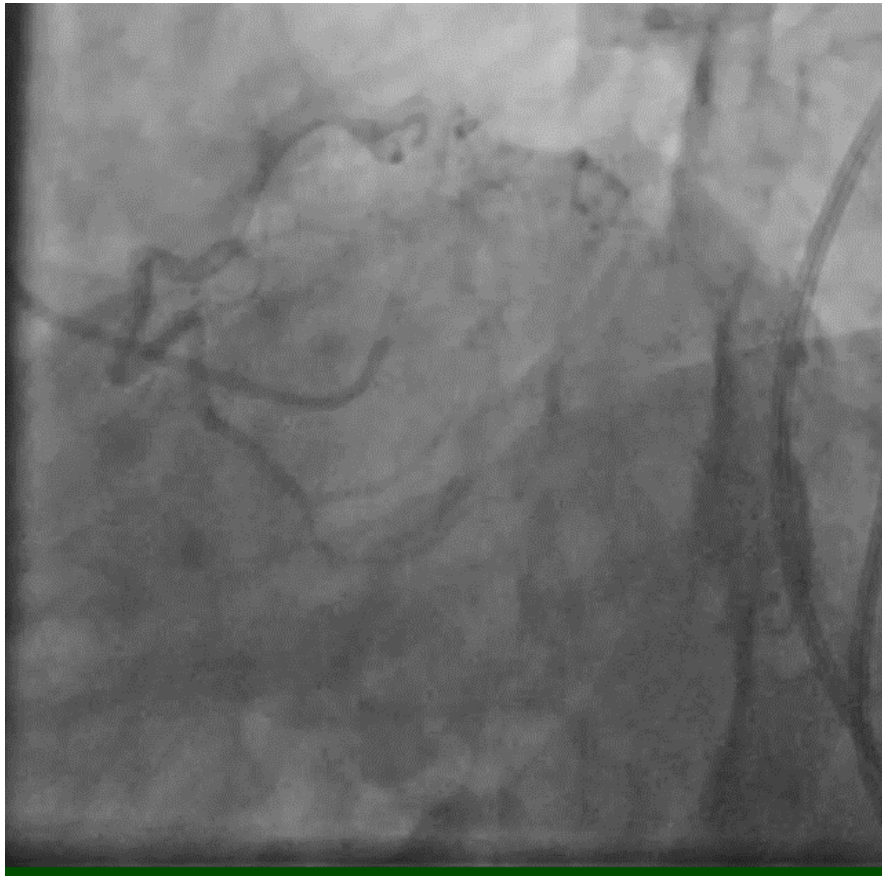


# Case 2

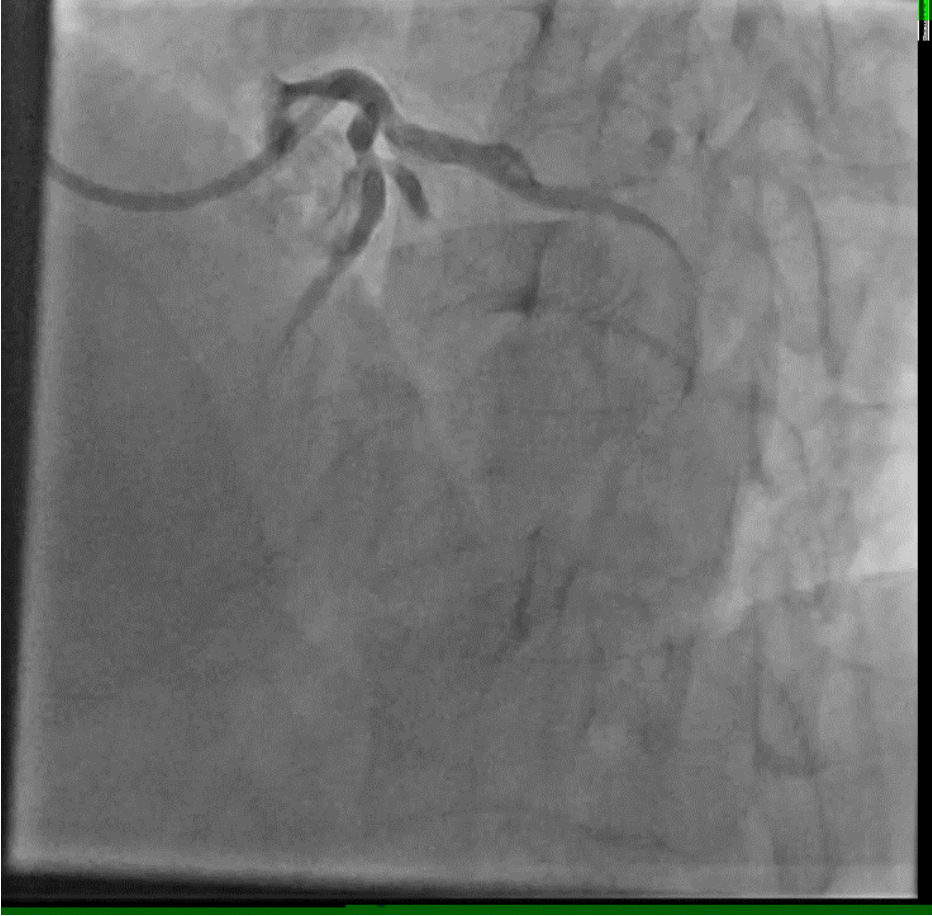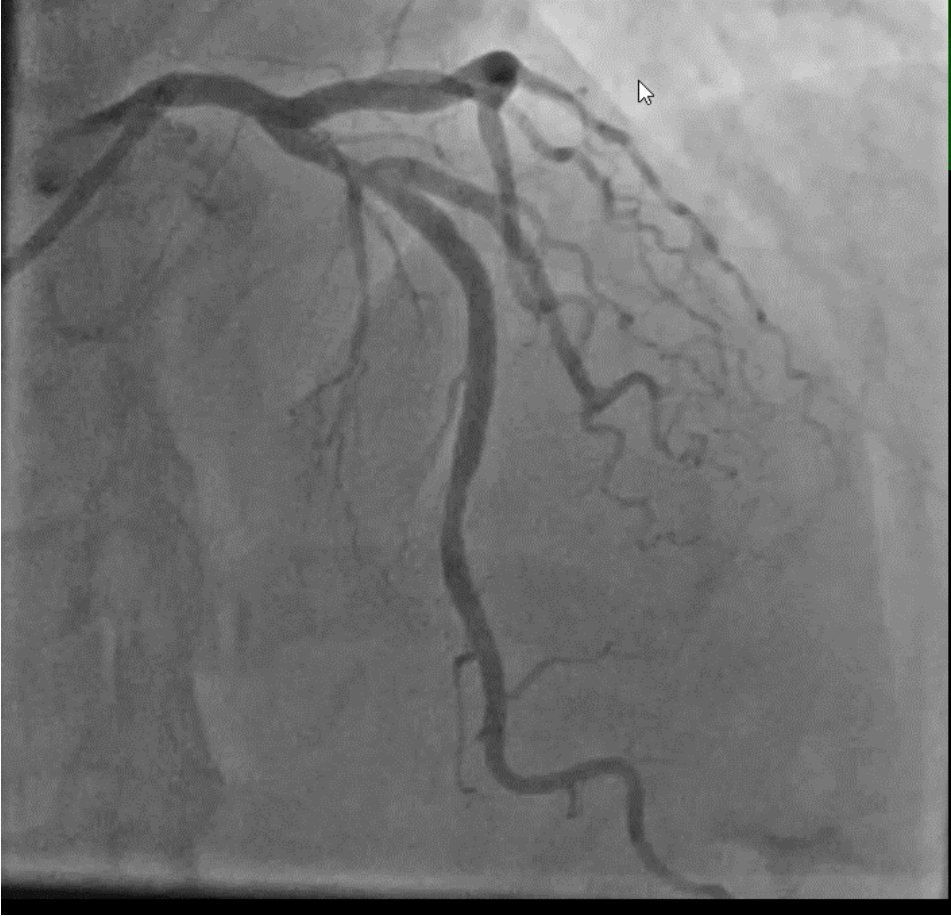## HO VAN T

- Bệnh nhân nam, 56 tuổi
- Vào viện đau thắt ngực
- Chẩn đoán: **STEMI**
- Tiền sử: Hút thuốc lá, Cường giáp đã điều trị

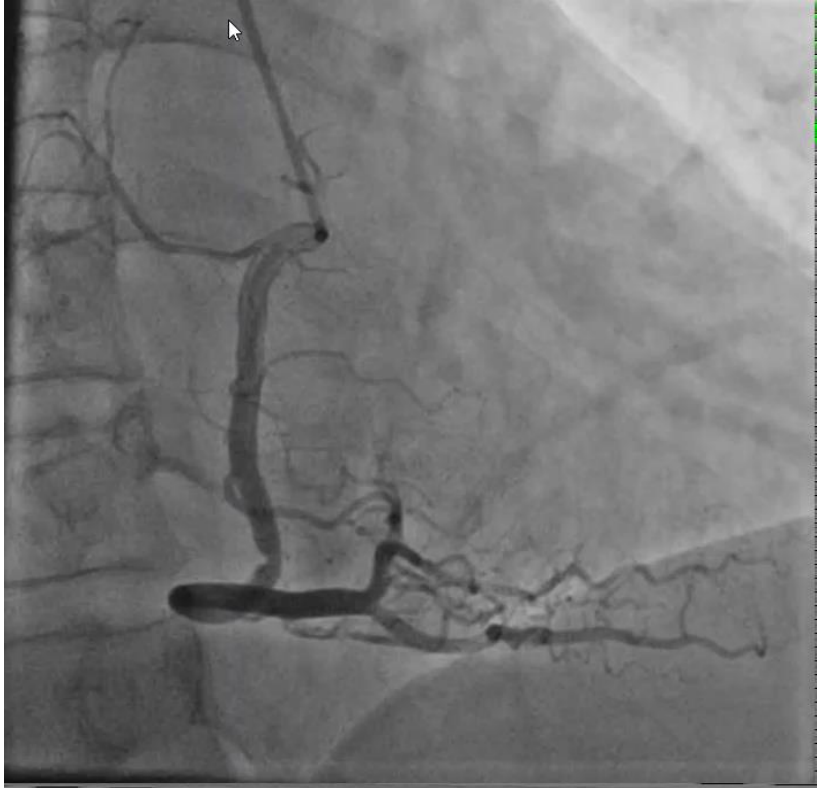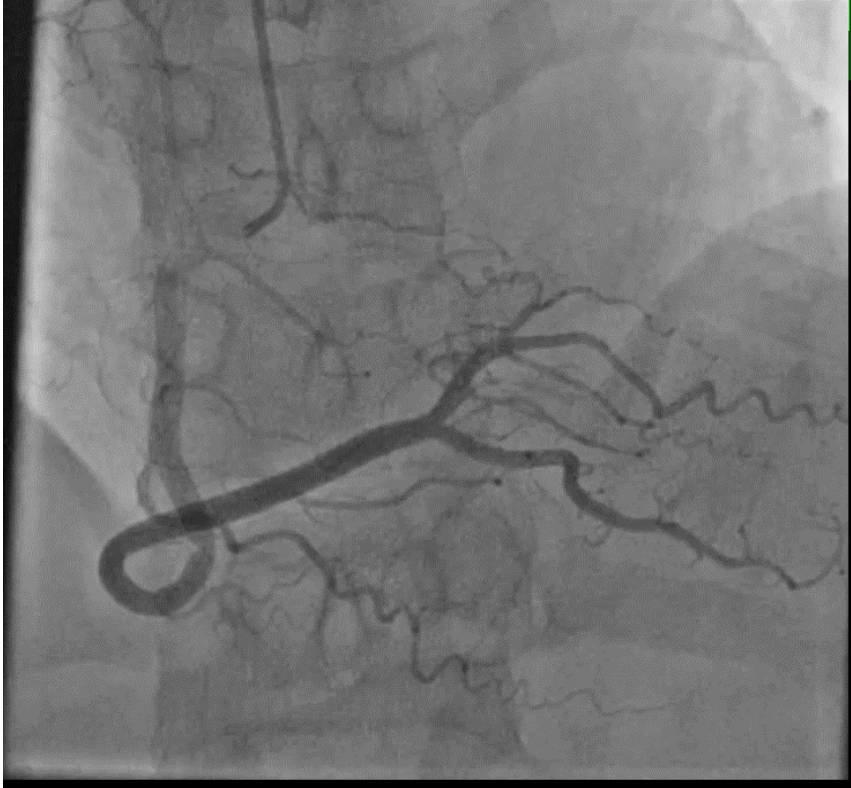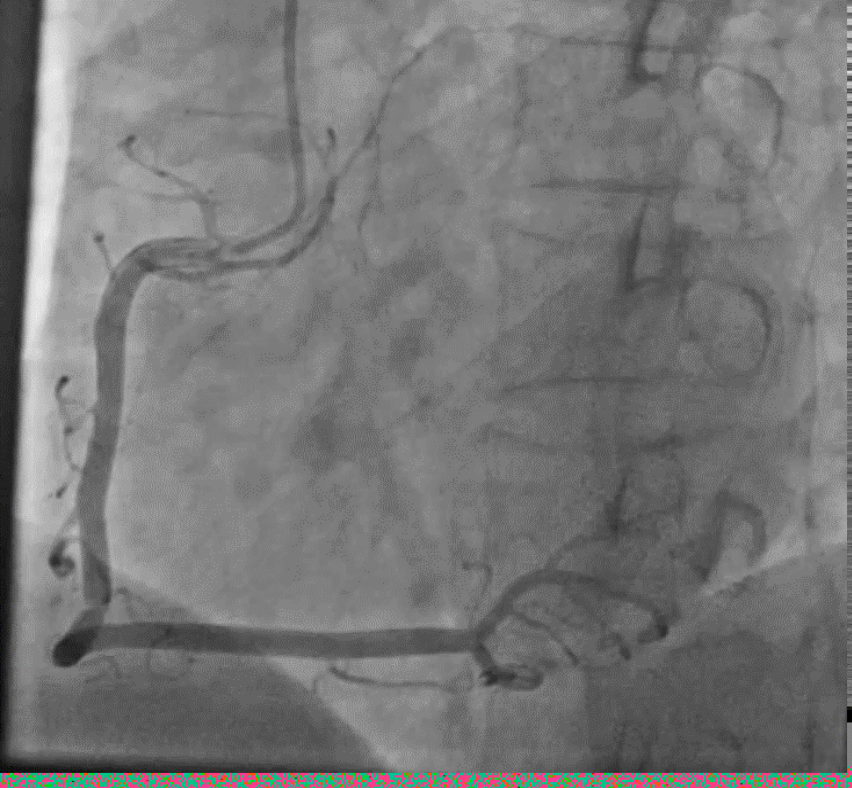# Angiogram



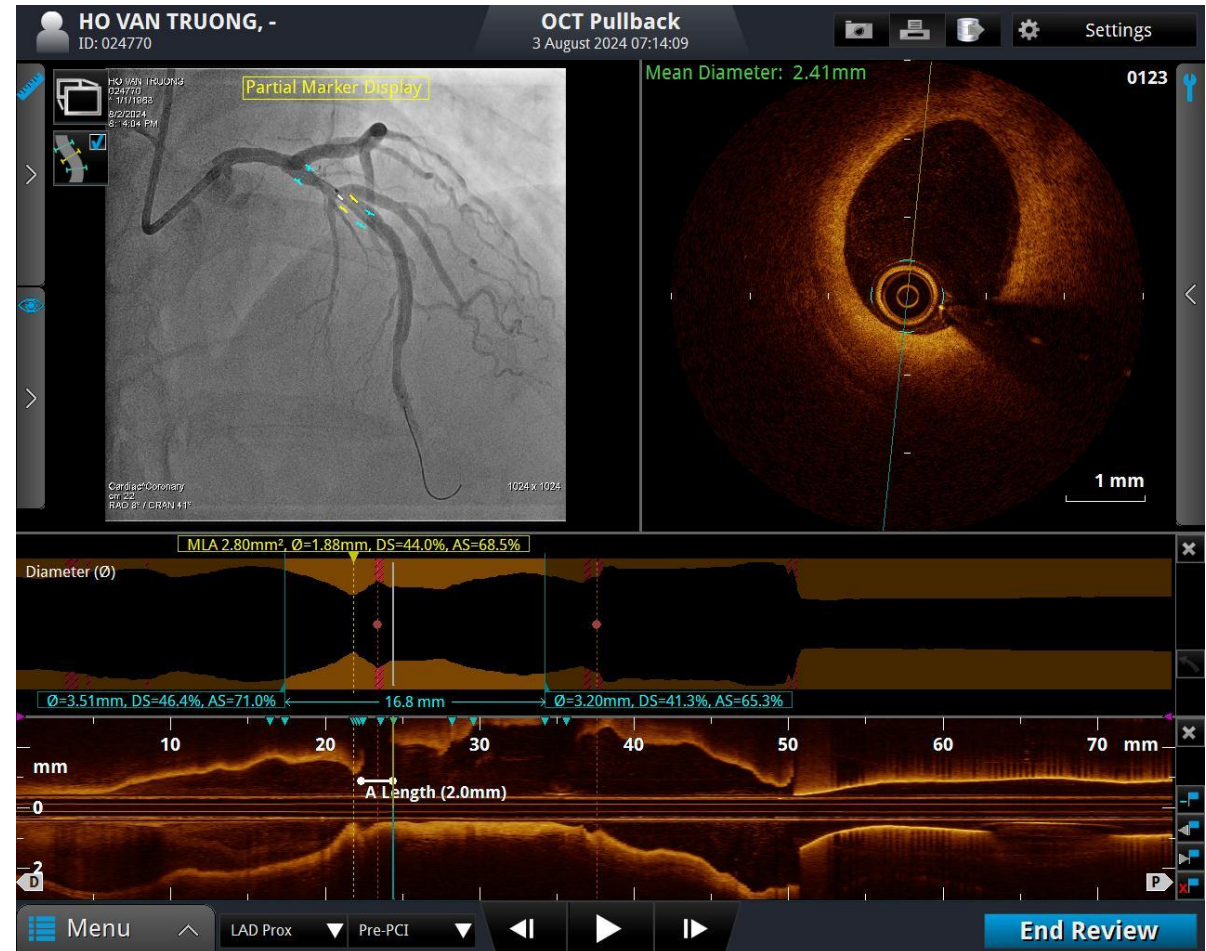
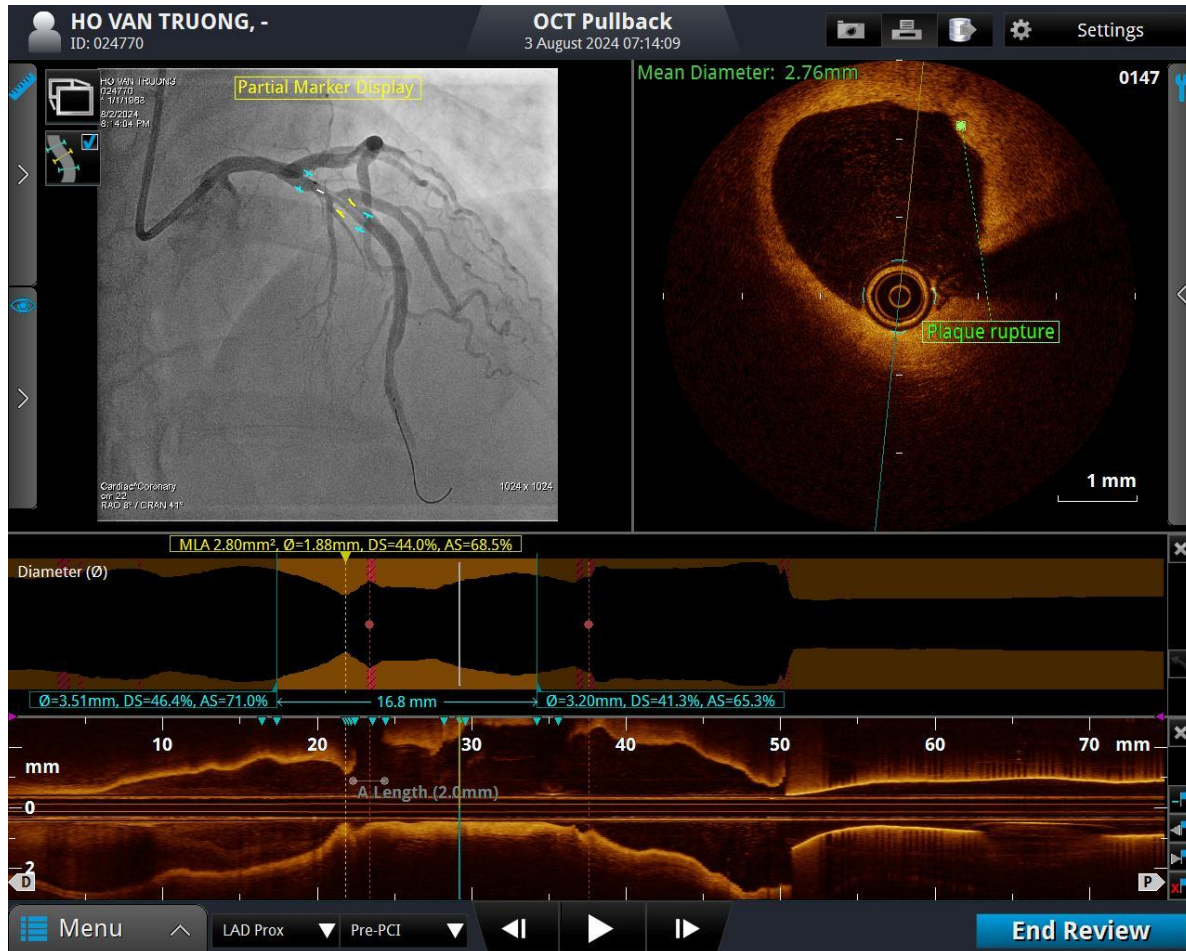
# Angiogram



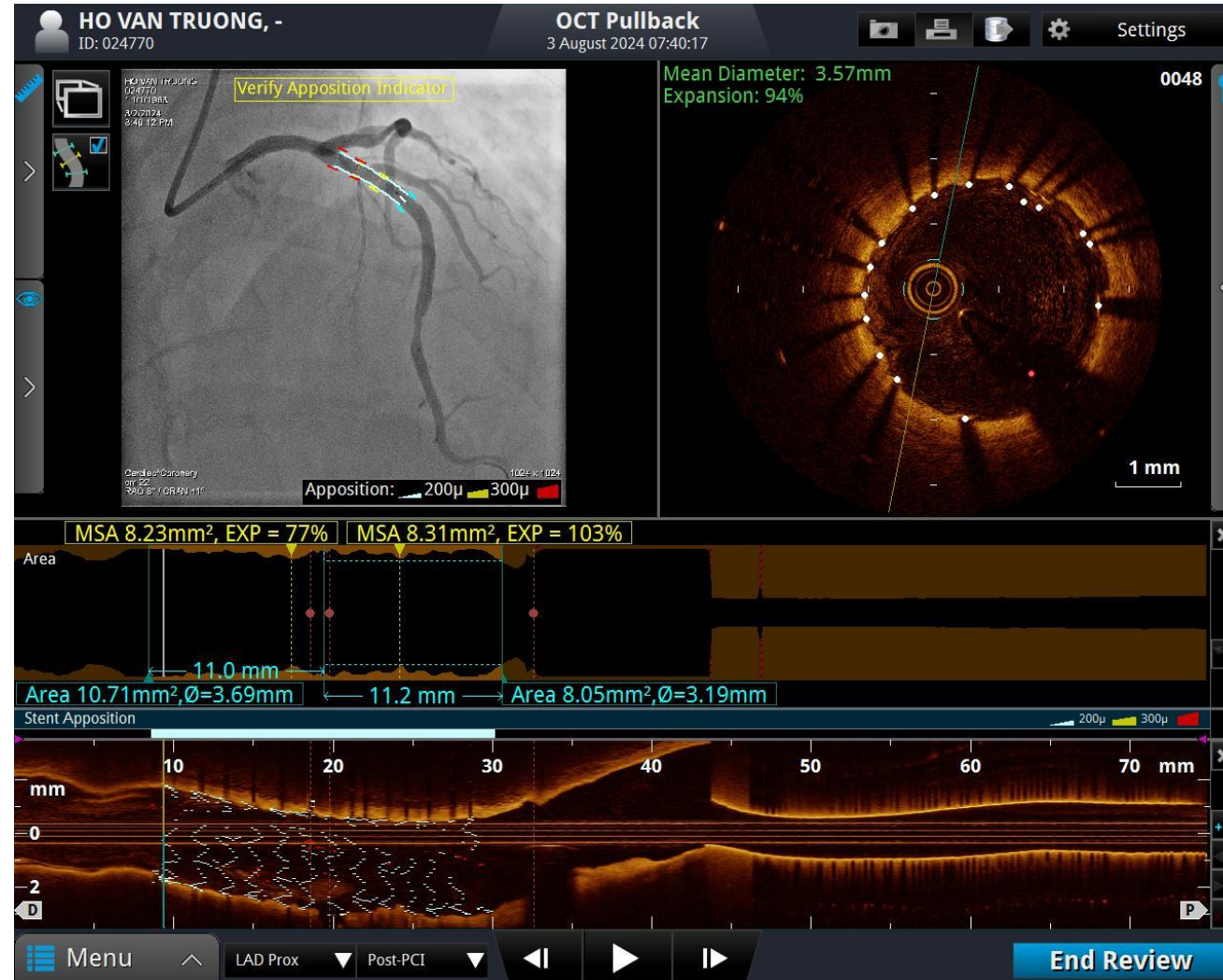
# Angiogram



# OCT



# MAX

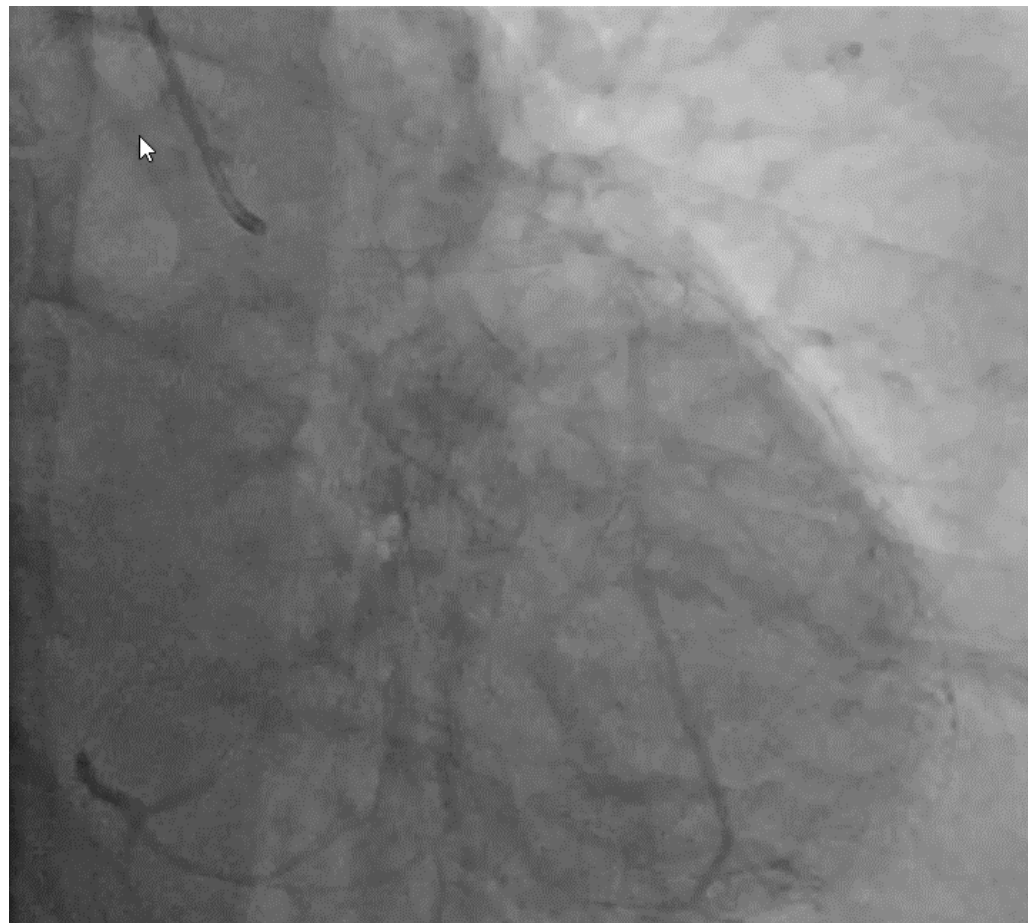


# Case 3

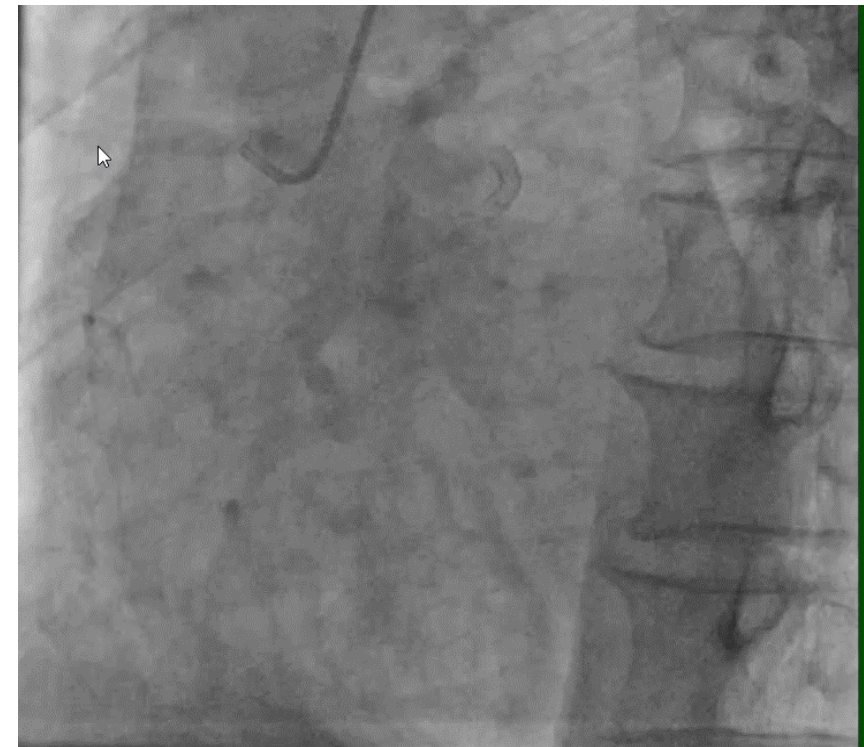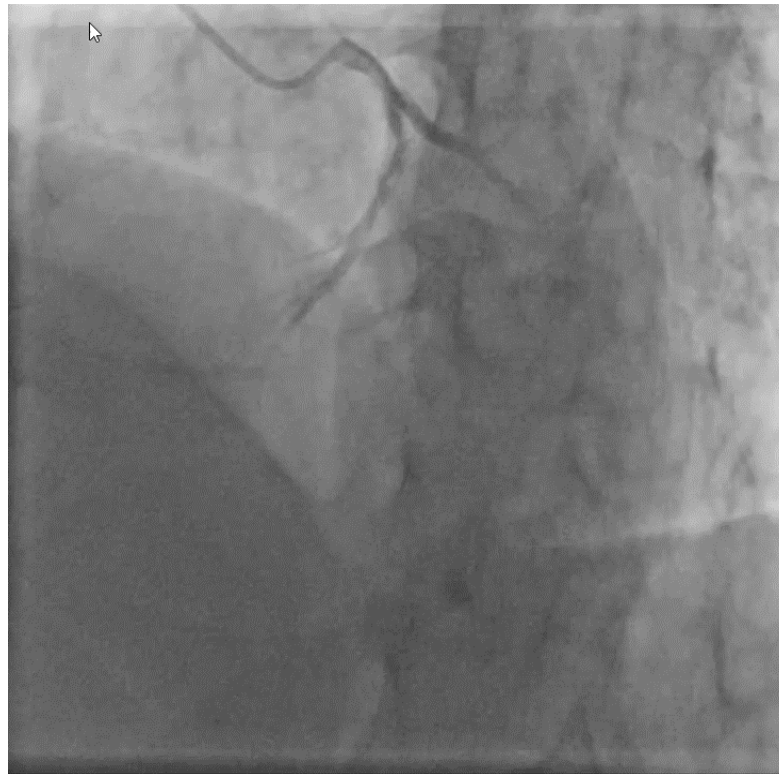
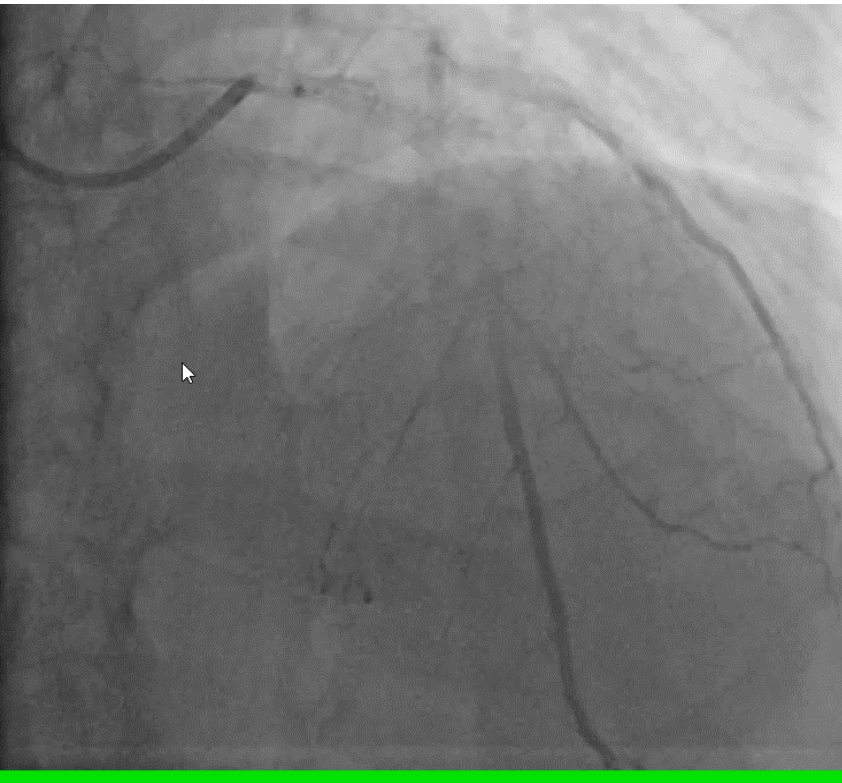
## NGO VAN L

- Bệnh nhân nam, 61 tuổi
- Vào viện vì đau thắt ngực
- Chẩn đoán: **NSTEMI**
- Tiền sử: Hút thuốc lá, THA, ĐTĐ, CAD stent 10 năm

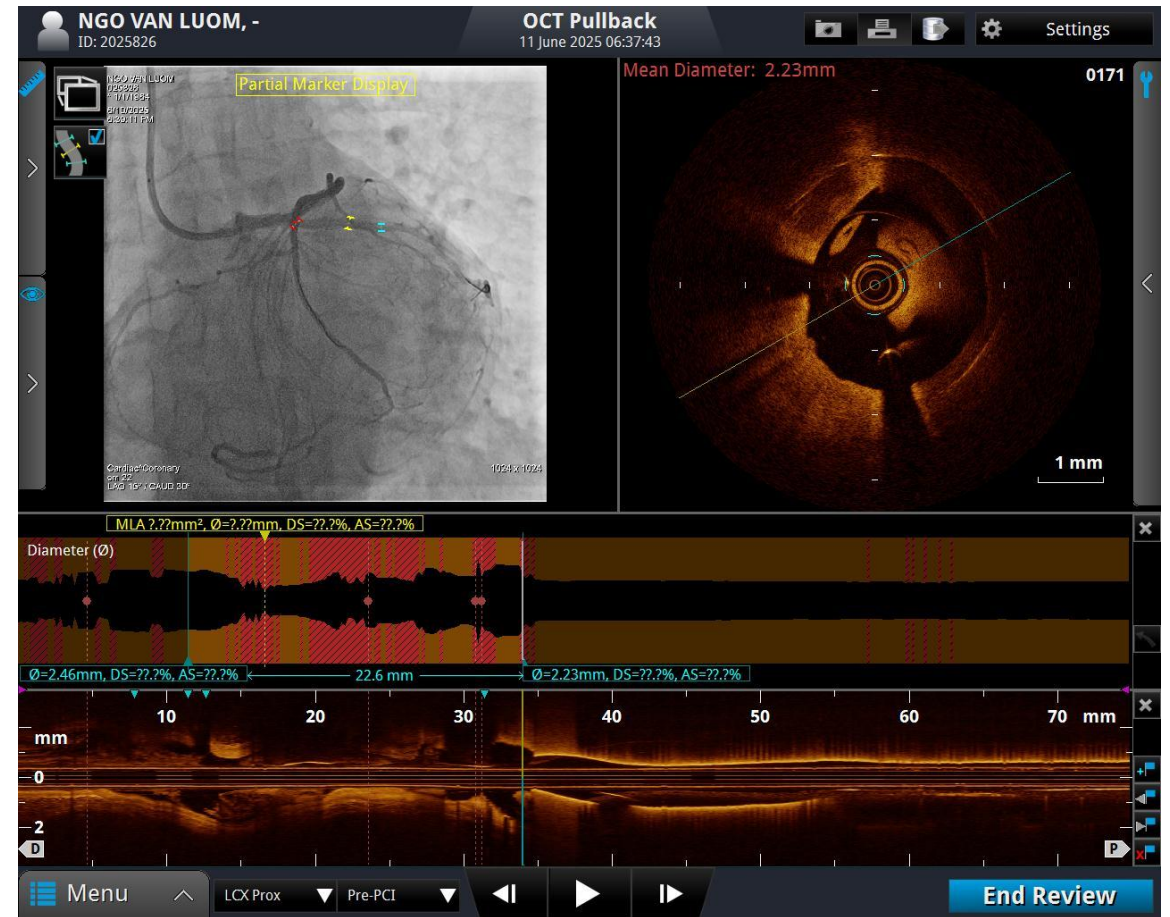
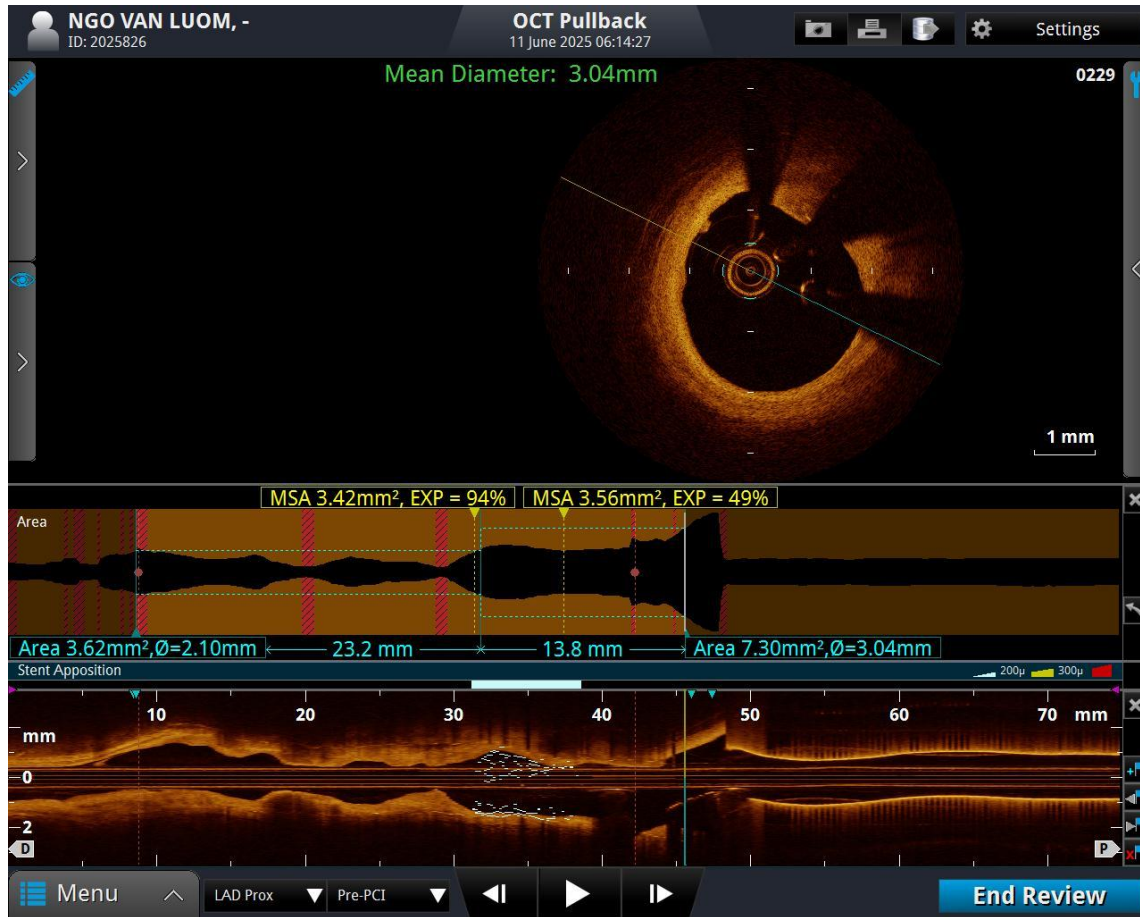
# Angiogram



# Angiogram



# MLD



# MAX

