



ASIC  
CONGRESS 2026

# CASE PRESENTATION

---

BS DANH TRẦN TRÍ  
BS CKII LÂM HỮU GIANG

# Patient Demographics:

- Gender: Male
- Age: 71
- Chief complaint: “Chest pain during exertion.”

## **Past Medical History**

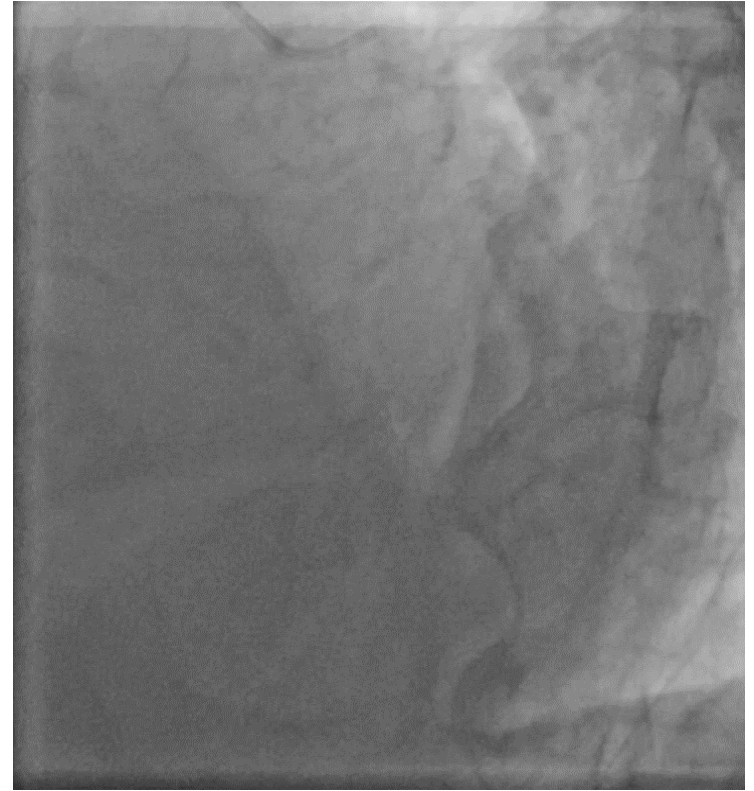
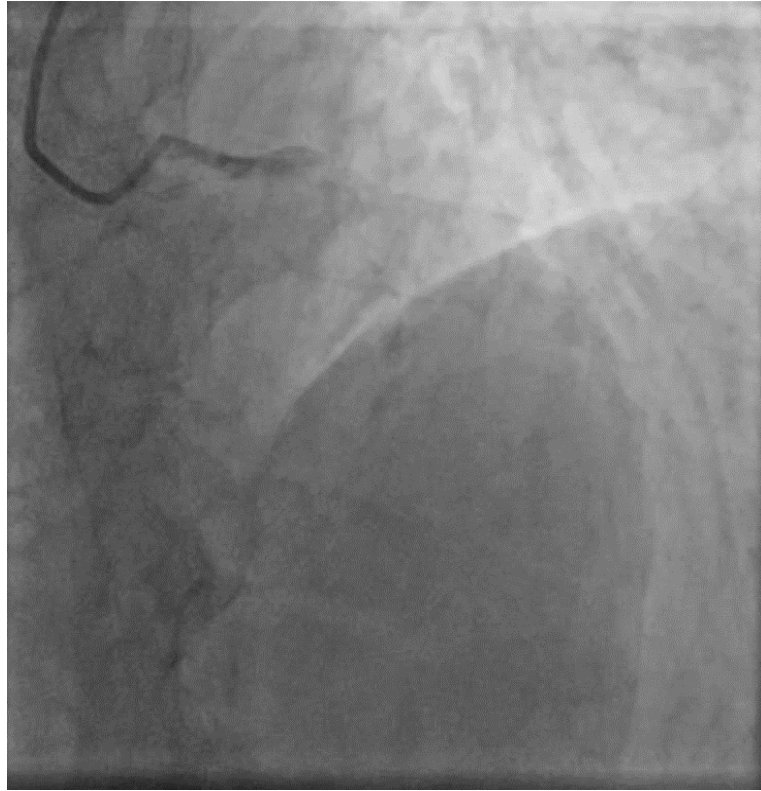
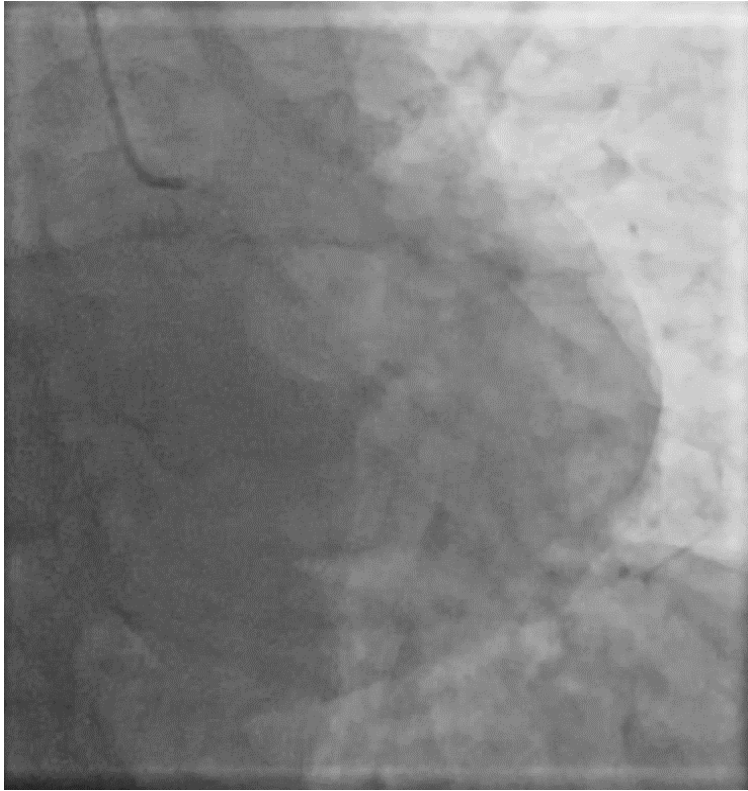
- Hypertension – 06 years
- Smoker – 25 pack-years
- Diabetes – 05 years
- No prior history of CAD or MI

Diagnose : Đau thắt ngực ổn định  
CCSIII /THA/ ĐTĐ típ 2

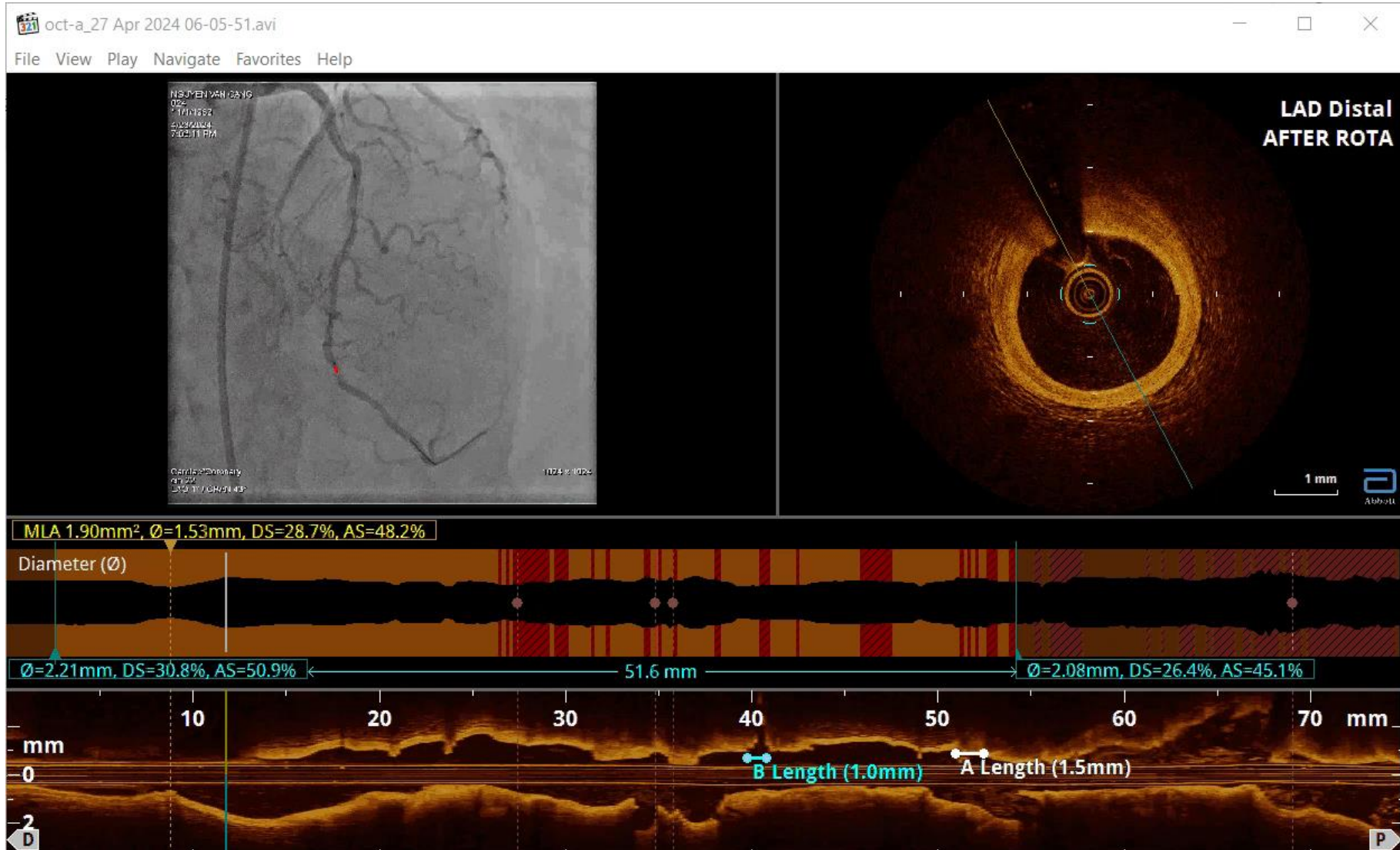
## **Medication History**

- Amlodipine 5 mg daily
- Metformin 850mg
- No history of aspirin or antiplatelets use

# CAG Results:



# OCT imagings



# Patient Demographics:

- Gender: Female
- Age: 72
- Chief complaint: “Chest pain during exertion.”

## **Past Medical History**

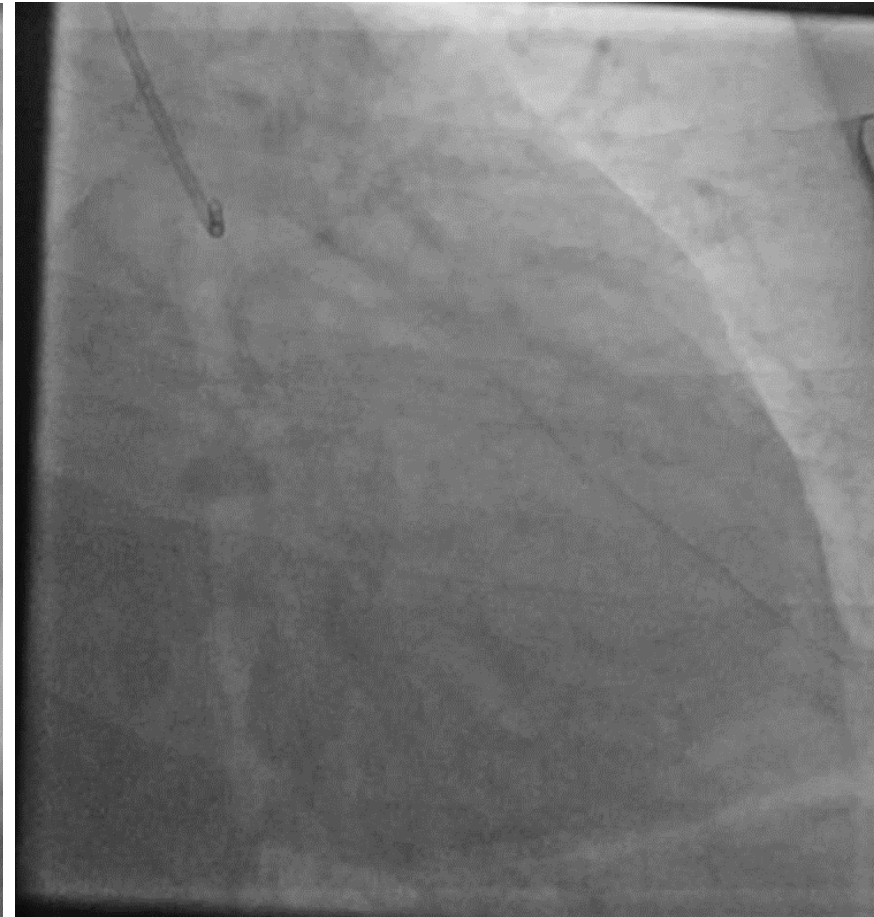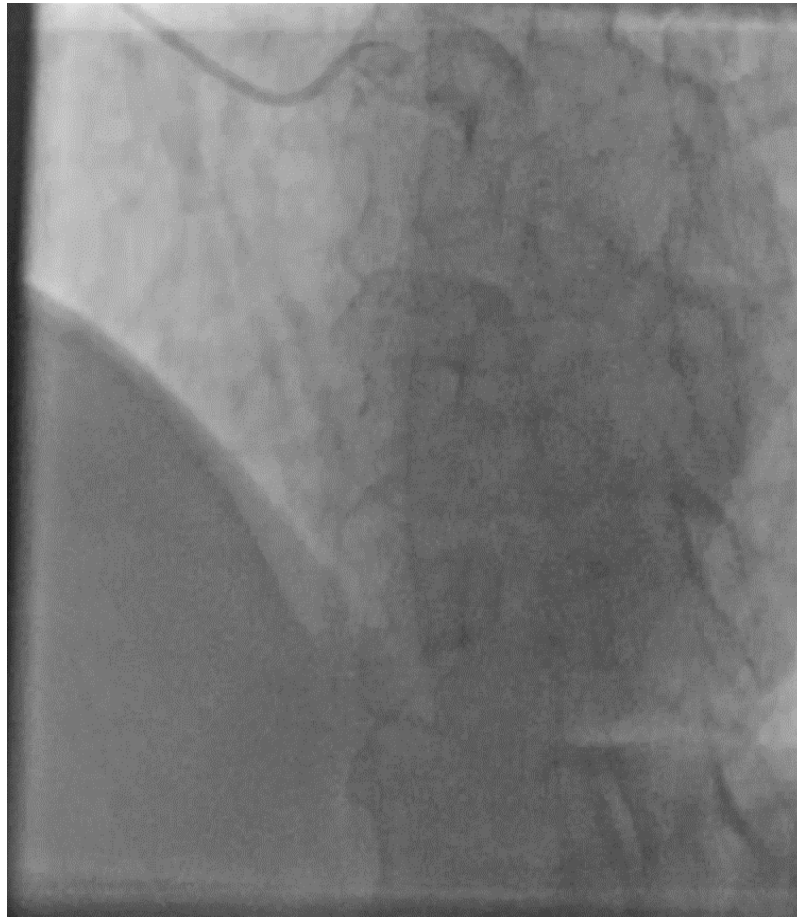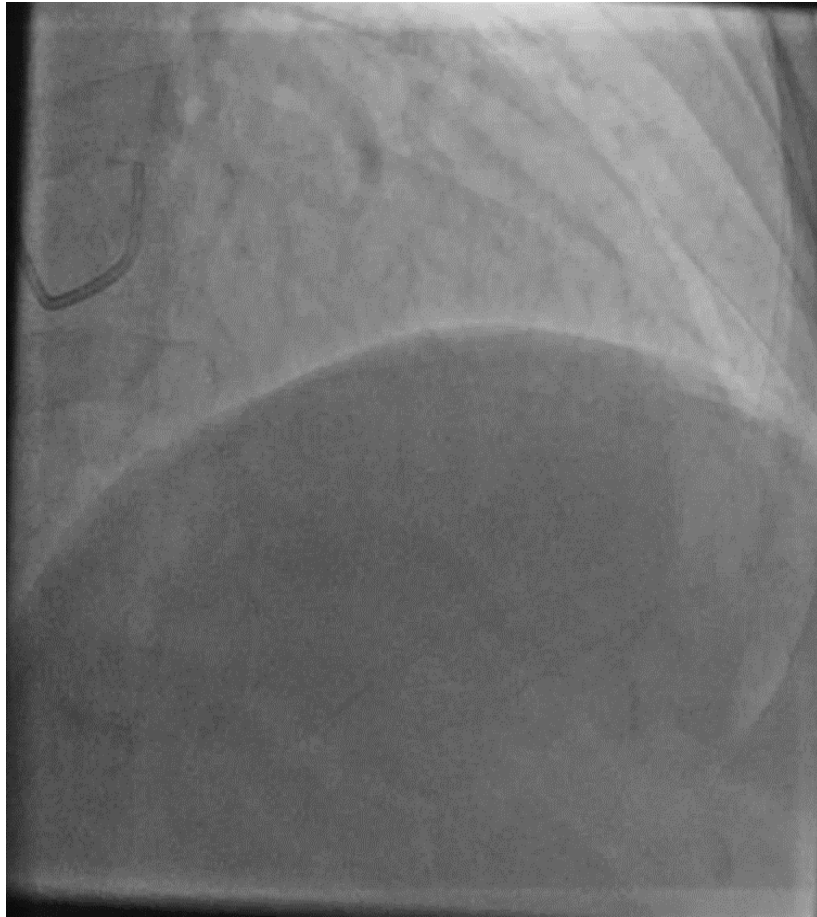- Hypertension – 10 years
- No prior history of CAD or MI

Diagnose : Đau thắt ngực ổn định  
CCSIII /THA

## **Medication History**

- Amlodipine 5 mg daily
- No history of aspirin or antiplatelets use

# CAG Results:



# OCT imagings

